



## Silent ischemic pancreatitis following urosepsis

Gülali Aktaş \*\*, Arif Duran<sup>b</sup>, Aytekin Alçelik<sup>a</sup>, Sevim Karaçay<sup>a</sup>, Haluk Şavlı<sup>a</sup>, Safiye Gürel<sup>c</sup>, Arzu Canan<sup>c</sup>

<sup>a</sup> Department of Internal Medicine, Izzet Baysal Medical Faculty, Bolu, Turkey

<sup>b</sup> Department of Emergency Medicine, Izzet Baysal Medical Faculty, Bolu, Turkey

<sup>c</sup> Department of Radiology, Izzet Baysal Medical Faculty, Bolu, Turkey

### ARTICLE INFO

### ABSTRACT

#### Article History

Received 24 / 04 / 2012

Accepted 09 / 05 / 2012

#### \* Correspondence to:

Gülali Aktaş  
Department of Internal Medicine,  
Medical Faculty,  
Abant Izzet Baysal University,  
Bolu, Turkey  
e-mail: draliaktas@yahoo.com

Pancreatic ischemia is an uncommon cause of acute pancreatitis. Ischemia with resultant pancreatitis has been reported in vasculitis, atheroembolism, intraoperative hypotension, survivors of cardiac arrest and hemorrhagic shock. Ischemic acute pancreatitis is difficult to recognize clinically. In this report we present a 63 year old woman with painless ischemic pancreatitis following urosepsis. We suggest that if a critically ill patient is hypotensive for more than 24-48 hours, amylase levels must be monitored to establish ischemic acute pancreatitis (AP) even if the patient remains asymptomatic.

*J. Exp. Clin. Med., 2013; 30:63-66*

#### Keywords:

Asymptomatics  
Hypotension  
Ischemic pancreatitis  
Urosepsis

© 2013 OMU

### 1. Introduction

Acute pancreatitis (AP) is a well described complication of various clinical entities. Several factors, mostly bile stones and alcohol consumption may cause AP. Hyperlipidemia and other metabolic disorders, autoimmune disorders, side effects of medications and ischemia are other well known causes of AP (Buchler et al., 2000).

Pancreatic ischemia is an uncommon cause of clinically significant pancreatitis. Ischemia with resultant pancreatitis has been reported in vasculitis, atheroembolism, intraoperative hypotension, survivors of cardiac arrest and hemorrhagic shock (Fernandez-del Castillo et al., 1991; Orvar and Johlin, 1994; Piton et al., 2010). Ischemia is also a consequence of septic shock. Reperfusion follows ischemic period and causes malfunction of microcirculation in pancreas. This malfunction is the critical factor of pathogenesis of acute pancreatitis (Klar et al., 1990; Hoffmann et al., 1995).

Ischemic AP is difficult to recognize clinically. Because it is usually accompanied by dysfunctions of other organ sys-

tems and the other causes of AP should be ruled out to define ischemia as the cause of AP. Risk of necrosis is higher in ischemic AP than other etiologies. Therefore early antibiotic treatment is necessary (Werner et al., 2005).

In this report we present a 63 year old woman with painless ischemic pancreatitis following urosepsis.

### 2. Case

A 63 year old woman was admitted to emergency department of our hospital because of impaired general condition. The patient also reported dizziness and weakness. Hypertension, diabetes mellitus, urolithiasis and surgery for spondylolisthesis were included in her medical history. At presentation, her body temperature was 37.5°C, blood pressure was 65/40 mmHg and heart-rate was 125 b.p.m. Physical examination revealed critically ill appearing woman. The abdomen was soft and non tender. There were no hepatosplenomegaly, palpable masses or ascites.

Laboratory findings on admission were as follows: He-

moglobin 10.3 g/dL, hematocrit 30.3%, white blood cell count 13.600/mm<sup>3</sup>, platelet count 231.000/mm<sup>3</sup>, mean corpuscular volume 84 femtoliter, blood urea 150 mg/dl, serum creatinin level 5.1 mg/dl, plasma glucose 242 mg/dl, aspartate aminotransferase (AST) 219 U/L, alanine aminotransferase (ALT) 247 U/L, gamma glutamyl transferase 214 U/L. Serum alkaline phosphatase, lactic dehydrogenase, amylase, bilirubin levels, triglycerides, calcium and coagulation tests were normal. Sedimentation rate was 31 mm/hour, c-reactive protein (CRP) was 376 mg/dL (normal value: 0-3.19 mg/dL). Urine microscopy revealed white cell count >500/per area, red cell count >500/per area, casts >15/per area. Urinary and blood cultures were negative. Telecardiography was normal except a mild cardiomegaly (Fig. 1) and electrocardiogram was normal.

Echocardiographic examination showed normal left cardiac functions and valves. An ultrasonography of the abdomen showed only a small abscess at the corticomedullary junction of the left kidney, otherwise normal. According to laboratory and clinical signs, we considered urinary tract infection, acute renal failure and septic shock. We had initiated saline infusion and meropenem 0.5 gr three times a day intravenously. Abdominal CT scan without administering contrast agent on the 3<sup>rd</sup> day of antibiotic therapy revealed partially resolved pelviciceal enlargement, bilateral pleural effusion and pancreatitis, although she has not complained of abdominal pain (Fig. 2). Therefore we reassessed serum amylase and detected an elevation up to 581 U/L (normal value: 5-125 U/L). Based on these findings, the patient was diagnosed with ischemic AP and treatment has been modified. Renal functions improved and elevated amylase levels decreased within 14 days of treatment. After stabilization, she was transferred to the department of urology for the surgery for urolithiasis.

### 3. Discussion

Shock, vascular occlusion in mesenteric vessels, cardiac arrest and cardiovascular surgery may lead acute ischemic pancreatitis (Gullo et al., 1996; Sakorafas et al., 2000; Piton et al., 2008; Drissi et al., 2009; Hackert et al., 2009; Piton et al., 2010). Ischemic AP frequency is estimated between 5% to 8% in literature (Warshaw and O'Hara, 1978; Sakorafas et al., 2000). Diagnosis of ischemic pancreatitis can be made by evaluation of medical history and clinical features, laboratory findings and CT scan (Balthazar, 2002). Restoration of circulatory function is essential for successful therapy in ischemic AP. Blood pressure must be maintained by intravenous fluid replacement and administration of vasopressor agents, if necessary. Because risk of necrosis is higher in ischemic AP than other causes, early antibiotic treatment is necessary (Werner et al., 2005). Antibiotic treatment with a broad antibacterial spectrum may be beneficial (Uhl et al., 2002; Villatoro et al., 2006). The patient in our report was hypotensive for 24-48 hours in emergency department although she had been infused saline solutions. Therefore vasopressor agents were administered. We also administered meropenem therapy for urosepsis in early stage of emergency room admission. These factors could be responsible for the mild course of ischemic AP in our case.

As blood flow is reserved for brain and vital organ systems when hypotension persists, it is possible that hypotension may induce ischemic pancreatitis. Authors suggest to

evaluate pancreatic injury especially in patients who develop sepsis from unknown origins even if the usual concomitants of pancreatitis are missing (Warshaw and O'Hara, 1978). In our case, the patient was diagnosed with sepsis originated from urinary tract and she has remained asymptomatic during the course of AP. She did not complain of digestive symptoms or abdominal pain although amylase level was elevated and pancreatic edema was detected by abdominal CT scan. Her serum amylase level before hypotensive period was normal on admission. She did not drink alcohol and her history was not associated with other causes of AP.

Impaired renal functions of the patient in the mentioned case may have been caused by postrenal reasons (urolithiasis), but also it may have been contributed by decreased renal blood flow following hypotension as a consequence of urosepsis. Because the kidney is the most vulnerable organ to acute injury in shock (Warshaw and O'Hara, 1978), hypotension may have caused both prerenal failure and ischemic pancreatitis at the same time in present case.

The patient did not complain of abdominal pain so initially we considered serum AST and ALT elevations were due to reversible ischemic hepatic injury, a more silent clinical entity. In present case, the patient had biochemically and radiologically acute pancreatitis without pain. Furthermore we learned that the patient had spinal cord surgery several times because of spondylolisthesis which may affect visceral senses of pain.

There are several painless acute pancreatitis cases in literature. Kobayashi et al. (2011) reported a painless AP in a patient receiving sorafenib treatment. The patient was 71 year old man with renal tumor. Swanson et al. (2003) reported a silent AP in a 22 year old man with congestive heart failure whom has been implanted a biventricular assist device. There are mild to moderate silent AP cases associated with antibiotics in literature (Ocal et al., 2010). But the patient in our case was not on any medications that are known to cause AP. In summary, this diabetic patient with urosepsis developed painless acute pancreatitis after 48 hours of hypotensive period. We suggest that if a critically ill patient is hypotensive for more than 24-48 hours, amylase levels must be monitored to establish ischemic AP even if the patient remains asymptomatic.

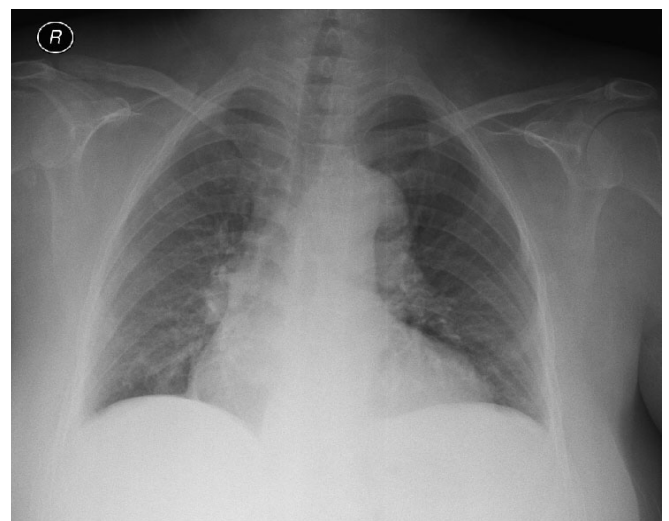
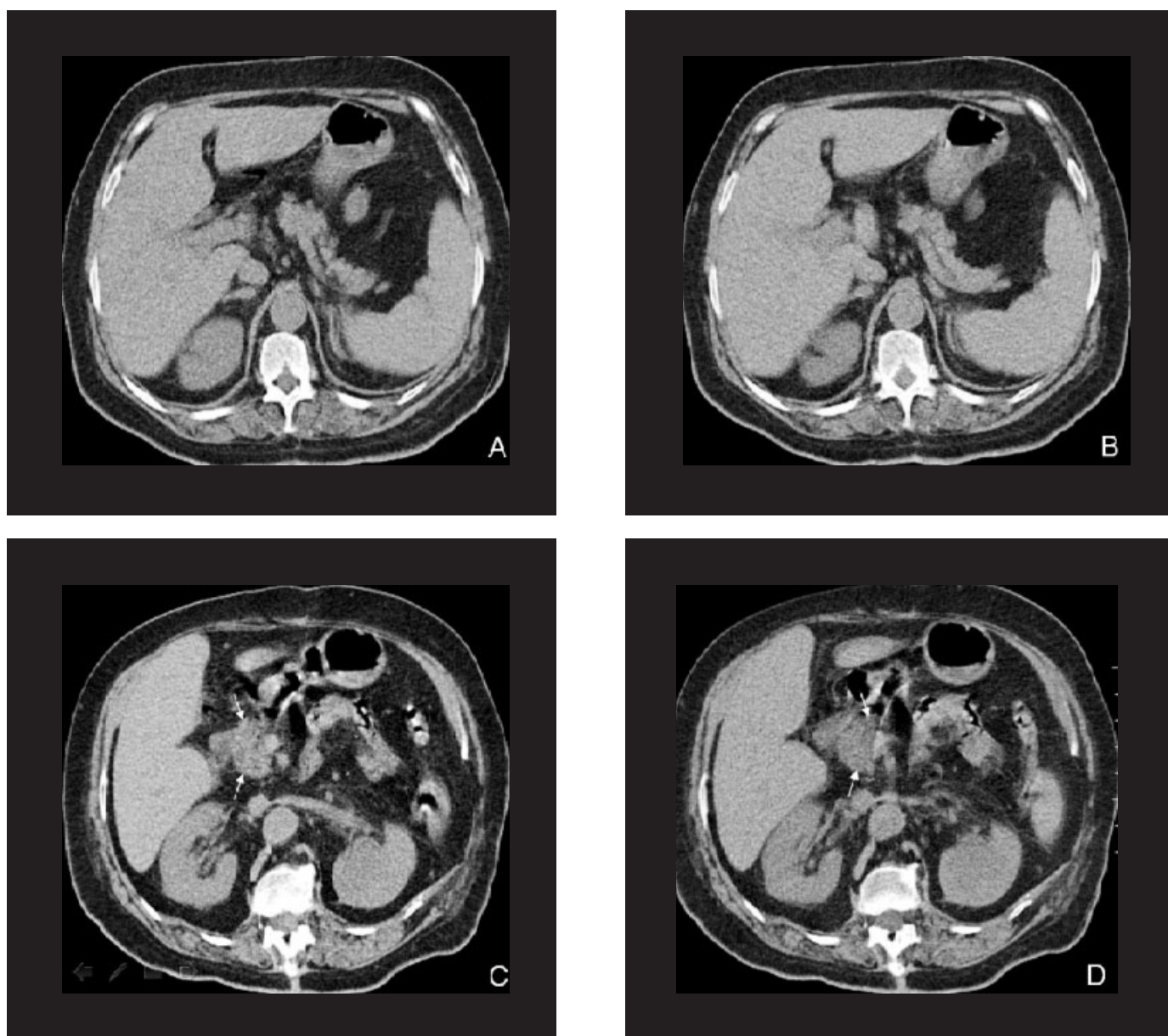


Fig. 1. Telecardiography of the patient



**Fig. 2.** Unenhanced consecutive MDCT images demonstrate nodular contour and fatty replacement indicating parenchymal atrophy of body and tail (A, B), in contrast with remarkable prominence and relative hypodensity (arrows) of pancreatic head (C, D).

## REFERENCES

- Balthazar, E.J., 2002. Acute pancreatitis: Assessment of severity with clinical and CT evaluation. *Radiology*. 223, 603-613.
- Buchler, M.W., Gloor, B., Müller, C.A, Friess, H., Seiler, C.A., Uhl, W., 2000. Acute necrotizing pancreatitis: Treatment strategy according to the status of infection. *Ann. Surg.* 232, 619-626.
- Drissi, M., Madani, M., Hatim, A., Ibat, D., Athmani, M., Taberkant, M., Houssa, M.A., Alaoui, M., Boulahya, A., 2009. Severe acute pancreatitis after surgical treatment of a ruptured abdominal aortic aneurysm. *Ann. Vasc. Surg.* 23, 785-787.
- Fernandez-del Castillo, C., Harringer, W., Warshaw, A.L., Vlahakes, G.J., Koski, G., Zaslavsky, A.M., Rattner, D.W., 1991. Risk factors for pancreatic cellular injury after cardiopulmonary by pass. *New Engl. J. Med.* 325, 382-387.
- Gullo, L., Cavicchi, L., Tomassetti, P., Spagnolo, C., Freyrie, A., D'Addato, M., 1996. Effects of ischemia on the human pancreas. *Gastroenterology*. 111, 1033-1038.
- Hackert, T., Hartwig, W., Fritz, S., Schneider, L., Strobel, O., Werner, J., 2009. Ischemic acute pancreatitis: Clinical features of 11 patients and review of the literature. *Am. J. Surg.* 197, 450-454.
- Hoffmann, T. F., Leiderer, R., Waldner, H., Arbogast, S., Messmer, K., 1995. Ischemia reperfusion of the pancreas: A new in vivo model for acute pancreatitis in rats. *Res. Exp. Med.* 195, 125-144.
- Klar, E., Endrich, B., Messmer, K., 1990. Microcirculation of the pancreas. A quantitative study of physiology and changes in pancreatitis. *Int. J. Microcirc. Clin. Exp.* 9, 85-101.
- Kobayashi, Y., Kanemitsu, T., Kamoto, A., Satoh, M., Mori, N., Sekii, K., Yoshioka, T., Itatani, H., Fujimoto, T., 2011. Painless acute pancreatitis associated with sorafenib treatment: A case report. *Med. Oncol.* 28, 463-465.
- Ocal, S., Selcuk, H., Korkmaz, M., Unal, H., Yilmaz, U., 2010. Acute pancreatitis following doxycycline and ornidazole coadministration. *JOP.* 11, 614-616.
- Orvar, K., Johlin, F.C., 1994. Atheromatous embolization resulting in acute pancreatitis after cardiac catheterization and angiographic studies.

- Arch. Intern. Med. 154, 1755-1761.
- Piton, G., Barbot, O., Manzon, C., Moronval, F., Patry, C., Navellou, J.C., Belle, E., Capellier, G., 2010. Acute ischemic pancreatitis following cardiac arrest: A case report. *JOP*. 11, 456-459.
- Piton, G., Navellou, J.C., Morati, P., Patry, C., Carbonnel, F., Capellier, G., 2008. Thrombotic thrombocytopenic purpura associated with severe acute pancreatitis in a context of decreased ADAMTS13 activity: A case report. *Eur. J. Gastroen. Hepat.* 20, 1226-1230.
- Sakorafas, G.H., Tsiotos, G.G., Sarr, M.G., 2000. Ischemia/Reperfusion-Induced pancreatitis. *Digest. Surg.*, 17, 3-14.
- Swanson, K.E., Ward, E. M., Wolfsen, H.C., 2003. Painless pancreatitis after implantation of a biventricular assistive device. *Transpl. P.* 35, 1546-1548.
- Uhl, W., Warshaw, A., Imrie, C., Bassi, C., McKay, C.J., Lankisch, P.G., Carter, R., Di Magno, E., Banks, P.A., Whitcomb, D.C., Dervenis, C., Ulrich, C.D., Satake, K., Ghaneh, P., Hartwig, W., Werner, J., McEntee, G., Neoptolemos, J.P., Büchler, M.W. International Association of Pancreatology., 2002. IAP guidelines for the surgical management of acute pancreatitis. *Pancreatology*. 2, 565-573.
- Villatoro, E., Bassi, C., Larvin, M., 2006. Antibiotic therapy for prophylaxis against infection of pancreatic necrosis in acute pancreatitis. *Cochrane Db. Syst. Rev.* 4, 294.
- Warshaw, A.L., O'Hara, P.J., 1978. Susceptibility of the pancreas to ischemic injury in shock. *Ann. Surg.* 188, 197-201.
- Werner, J., Hartwig, W., Hackert, T., Büchler, M.W., 2005. Surgery in the treatment of acute pancreatitis-open pancreatic necrosectomy. *Scand. J. Surg.* 94, 130-134.