



Available online at [www.sciencedirect.com](http://www.sciencedirect.com)

ScienceDirect

journal homepage: <http://www.kjms-online.com>



Original Article

# Optical coherence tomography findings in Parkinson's disease



Turkoglu Sule Aydin <sup>a</sup>, Dogan Umit <sup>b</sup>, Ogun Muhammed Nur <sup>a,\*</sup>, Ulas Fatih <sup>b</sup>, Keles Asena <sup>b</sup>, Ozturk Yavas Nefise <sup>a</sup>, Yildiz Serpil <sup>a</sup>

<sup>a</sup> Department of Neurology, Faculty of Medicine, Abant Izzet Baysal University, Bolu, Turkey

<sup>b</sup> Department of Ophthalmology, Faculty of Medicine, Abant Izzet Baysal University, Bolu, Turkey

Received 12 March 2017; accepted 14 November 2017  
Available online 6 December 2017

## KEYWORDS

Parkinson's disease;  
Coherence  
tomography;  
Optical

**Abstract** The aim of this study is to compare optical coherence tomography (OCT) findings of retinal thickness (RT) and retinal nerve fiber layer thickness (RNFLT) of idiopathic Parkinson's disease (IPD) patients to those of healthy subjects, and to investigate whether there is any relationship between the severity of the disease and the RNFLT values. This prospective study was included 25 IPD patients and 29 healthy controls. In the IPD group, the Hoehn and Yahr (H&Y), *Unified Parkinson's Disease Rating Scale* (UPDRS), and Mini-Mental State Exam (MMSE) were performed. Intraocular pressure (IOP), visual acuity (VA), spherical equivalent, axial length (AL), and central corneal thickness (CCT) were measured using OCT in both groups. The RT was measured in the central retinal (RTc), nasal (RTn), and temporal (RTt) segments. Nasal (RNFLTn), nasal superior (RNFLTns), nasal inferior (RNFLTni), temporal (RNFLTt), temporal superior (RNFLTts), and temporal inferior (RNFLTti) measurements were made and mean RNFLT was calculated (RNFLTg) for each individual. In the patient group, IOP and VA values were statistically significantly lower. The RTn and RNFLTg were significantly thinner in the patient group. There was no statistically significant relationship between the severity of IPD and these findings. In our study, RNFLTg and RTn were found to be thinner in the IPD group, which may have caused lower VA scores. The effects of retinal dopamine depletion on RT and RNFLT, and lower IOP values in the non-glaucomatous IPD patients should be further investigated. Copyright © 2017, Kaohsiung Medical University. Published by Elsevier Taiwan LLC. This is an open access article under the CC BY-NC-ND license (<http://creativecommons.org/licenses/by-nc-nd/4.0/>).

Conflicts of interest: All authors declare no conflicts of interest.

\* Corresponding author. Abant Izzet Baysal University Hospital, Department of Neurology, 14280, Bolu, Turkey.  
E-mail address: [dr.mogun@gmail.com](mailto:dr.mogun@gmail.com) (O.M. Nur).

<https://doi.org/10.1016/j.kjms.2017.11.006>

1607-551X/Copyright © 2017, Kaohsiung Medical University. Published by Elsevier Taiwan LLC. This is an open access article under the CC BY-NC-ND license (<http://creativecommons.org/licenses/by-nc-nd/4.0/>).

## Introduction

Idiopathic Parkinson's disease (IPD) is a neurodegenerative disorder accompanied by motor and non-motor symptoms [1]. The main motor features of IPD are primarily linked to the selective degeneration of dopaminergic neurons located in pars compacta of substantia nigra, which leads to a severe depletion of dopamine in the striatum [2].

Dopamine dysfunction is seen not only in basal ganglia but also in retina, particularly in the horizontal and amacrin, bipolar, and ganglion cells. In an autopsy study in eight patients with IPD, Harnois et al. [3] found reduced dopamine levels in the retina.

Optical coherence tomography (OCT) is a potential biomarker for IPD [4,5]. It is an optical signal acquisition and processing method which measures the differences in optical properties of different layers of tissues. The retinal nerve fiber layer thickness (RNFLT) may predict the severity of IPD [6,7]. In a study, Altintas et al. [8] demonstrated a relationship between the severity of IPD and retinal thickness (RT) measured by OCT.

However, review of the relevant literature on the RNFLT in IPD has yielded controversial findings. In some studies, the RNFLT was found to be significantly thinner in the patients with IPD, whereas some of them reported RNFLT loss in the temporal quadrant [6–14].

On the other hand, in a recent study including 34 patients with IPD and 17 healthy controls, Archibald et al. [15] reported no significant differences in the RNFLT between the groups. Other four recent studies have also shown no significant differences in the RNFLT between the IPD and control groups [16–19]. The aim of this study is to determine whether the RT and RNFLT are different in patients with IPD from healthy individuals and to investigate whether there is a relationship between the severity of IPD and these thicknesses.

## Methods

This prospective study included a total of 25 patients with IPD who were admitted to Abant İzzet Baysal University, Education and Research Hospital, Bolu, Turkey and a control group consisting of 29 healthy individuals between 2014 and 2015. The study was approved by the local Ethics Committee (no: 2013/69) and conducted in accordance with the Declaration of Helsinki. All participants were informed about the study and a written informed consent was obtained from each participant.

Patients having any systemic diseases, any ophthalmic surgery, except cataract surgery without any complication, refraction error  $>5$  spherical diopters or  $>3$  cylindrical diopters, and conditions affecting retina and optic nerve, such as glaucoma or macular degeneration were excluded from the study. The diagnosis of was made according to the United Parkinson's Disease Rating Scale (UPDRS). Only patients with IPD were included in this study, while those with secondary Parkinsonism were excluded.

Neurological evaluation was performed by a single experienced neurologist in both groups. The modified Mini-Mental State Examination (MMSE), Hoehn and Yahr (H&Y)

scale, and UPDRS were administered to the patients with IPD.

## Ophthalmic evaluation

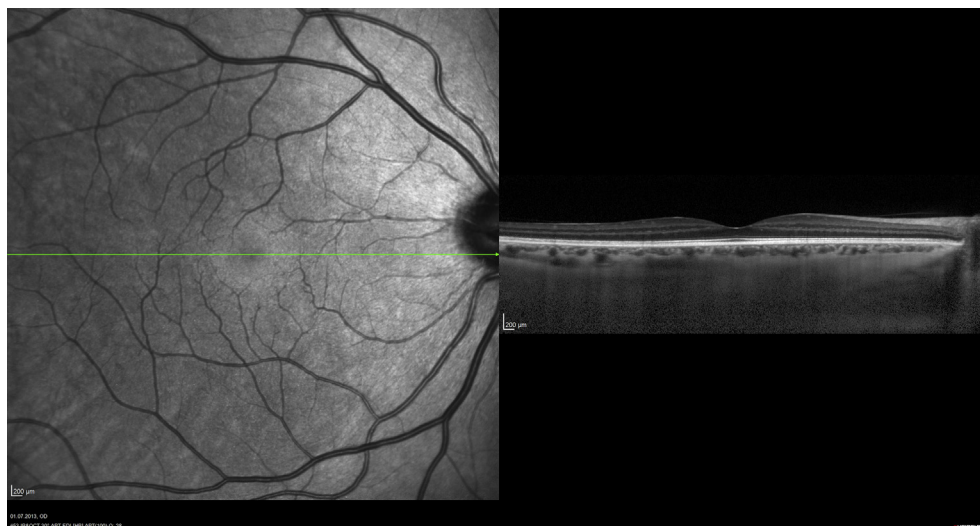
Each participant underwent a detailed ophthalmic examination, including the best recovered visual acuity (VA), anterior and posterior segmental biomicroscopic examination, and intraocular pressure (IOP) measurement. Visual acuity was measured by a Snellen chart and converted to logMAR. Intraocular pressure was measured by non-contact tonometer.

All OCT examinations were carried out simultaneously by a single experienced physician. To provide the reliability of the measurements, only the images with a signal strength level  $>20$ , which are above the recommended signal strength level in OCT images, were obtained. The OCT examinations were performed using the Spectralis OCT device (Heidelberg Engineering, Heidelberg, Germany-Software version 5.3).

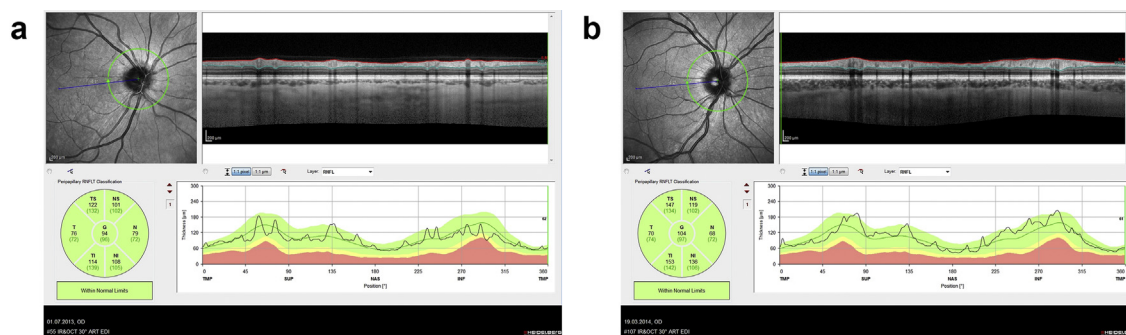
For each participant, an OCT image of a horizontal section passing through the central fovea was taken, and three RT measurements were obtained from points at the center of the fovea, at 1500  $\mu\text{m}$  from the fovea in its nasal macula, and at 1500  $\mu\text{m}$  from the fovea in its temporal macula, respectively (Fig. 1). All images were obtained without changing any settings of enhanced depth imaging (EDI), already existing in the OCT device to provide standardization of measurements for each subject. The RNFLT was measured without changing any settings of measurement mode, already existing in the OCT device. Spherical equivalent, axial length (AL), central (RTc), nasal (RTn) and temporal (RTt) thickness measurements were compared in the patient and control group. The central corneal thickness (CCT), nasal (RNFLTn), nasal superior (RNFLTns), nasal inferior (RNFLTni), temporal (RNFLTt), temporal superior (RNFLTts), and temporal inferior (RNFLTti) thickness were measured for each participant (Fig. 2a–b). The RNFLT global (RNFLTg) was calculated as the mean of the RNFLT measurements.

## Statistical analysis

Statistical analysis was performed using the SPSS for Windows version 17.0 (SPSS Inc., Chicago, IL, USA). Descriptive statistics were expressed in mean  $\pm$  standard deviation (SD). The chi-square test was used to compare the distribution of age and sex between the patient and control groups. The independent sample *t*-test was used to investigate whether there was any significant difference between the IPD and control groups having normally distributed data in terms of OCT findings and obtained data. The Mann–Whitney *U* test was used compare the groups having abnormally distributed data. The correlation between the MMSE and UPDRS scores and VA, IOP, and RNFLT in both groups was analyzed using the analysis of variance (ANOVA) and Pearson's correlation analysis. A *P* value of less than 0.05 was considered statistically significant.



**Figure 1.** Images of central fovea in the horizontal section passing through the fovea, nasal and temporal segments, 1500  $\mu\text{m}$  from fovea were used. The images were obtained without changing any settings of enhanced-depth imaging (EDI), already existing in the OCT device.



**Figure 2.** (a) The measurement of the RNFLT in the patient group. (b) The measurement of the RNFLT in the control group.

## Results

Of a total of 25 patients, 17 were males and eight were females with a mean age of 70 (range: 50–82) years. Of 29 healthy individuals, 19 were males and 10 were females with a mean age of 68 (range: 59–78) years. There was no statistically significant difference in the male-to-female ratio and mean age between the patient and control groups ( $P = 0.851$  and  $P = 0.962$ , respectively). In addition, there was no significant difference in the spherical equivalent, AL, and CCT values between the groups ( $P > 0.05$ ) (Table 1). However, in the patient group, the IOP and VA values were significantly lower than the control group ( $P < 0.001$  and  $P = 0.010$ , respectively) (Table 1). The RTc, RTn, and RTt thickness were also thinner in the patient group compared to the control group ( $P = 0.011$ ) (Table 1). Also, the RNFLTn, RNFLTns, RNFLTni, RNFLTt, RNFLTts, and RNFLTti measurements were found to be thinner in the IPD group than the control group, although it did not reach statistical significance ( $P > 0.05$ ). Only RNFLTg was found to be significantly thinner in the IPD group than the control group ( $P = 0.021$ ).

In IPD group, the median duration of illness was 48 (range 2–192) months, the median H&Y point was 1 (0–5), the median MMSE score was 28 (21–30), and the median UPDRS score was 24 (4–74). According to the Pearson's correlation analysis, there was no correlation between the MMSE and UPDRS scores and VA, IOP, RTn, and RNFLTg values ( $P > 0.05$ ) (Table 2).

## Discussion

Optical coherence tomography is a cost-effective, rapid, and non-invasive optical interferometric method generating cross-sectional images of the retina. It is a reliable tool which enables quantitative assessment of RNFLT for diagnose and follow-up of neurological and neurodegenerative conditions including migraine, optic neuritis, Alzheimer's disease, and multiple sclerosis [20–24].

Although IPD is a common disease among aging population, accuracy of the clinical diagnosis of IPD is still limited. Diagnosis may be delayed due to lack of characteristic findings in magnetic resonance imaging (MRI) and computed

**Table 1** Demographic characteristics and OCT findings of patient and control groups.

	Group		P
	IPD group (n = 25)	Control group (n = 29)	
Sex			
Male (n)	17	19	0.851
Female (n)	8	10	
	<b>Mean ± Standard Deviation**</b>		
AL (mm)	22.8 ± 0.7	23.2 ± 0.9	0.112
CCT (µm)	546.4 ± 28.3	535 ± 97.8	0.615
IOP (mmHg)	13.6 ± 2.6	15.7 ± 3.3	<b>0.010</b>
RTc (µm)	219 ± 17.8	219.9 ± 22.6	0.941
RTn (µm)	334.2 ± 16.7	346.6 ± 17.4	<b>0.010</b>
RTt (µm)	314.7 ± 18	323.3 ± 16.7	0.125
RNFLTg (µm)	97.1 ± 12.8	104 ± 7.1	<b>0.021</b>
RNFLTn (µm)	74.3 ± 18.3	78.6 ± 10	0.326
RNFLTns (µm)	102.2 ± 27.2	111.2 ± 21.7	0.212
RNFLTts (µm)	130.4 ± 28.8	140.4 ± 15.5	0.119
	<b>Median (Min–Max.)***</b>		
Spherical equivalent	0.50 (–5–3.25)	0.00 (–5–4.25)	0.114
VA (logMAR)	0.1 (0–0.50)	0.0 (0.0–0.0)	<b>&lt; 0.01</b>
RNFLTni	107 (70–179)	116 (83–167)	0.181
RNFLTt	72 (44–124)	74 (54–97)	0.332
RNFLTti	145 (91–214)	149 (128–192)	0.142
Age (year)	70 (50–82)	68 (59–78)	0.960

\*Pearson Chi-Square Test, \*\* Independent samples *t*-test, \*\*\* Mann–Whitney *U* Test.

IPD: Idiopathic Parkinson Disease, AL: Axial Length, CCT: Central Corneal Thickness, VA: Visual Acuity, RTc: Central Retinal Thickness, RTn: Nasal Retinal Thickness, RTt: Temporal Retinal Thickness, RNFLTn: Nasal Retinal Nerve Fiber Layer Thickness, RNFLTns: Nasal Superior Retinal Nerve Fiber Layer Thickness, RNFLTni: Nasal Inferior Retinal Nerve Fiber Layer Thickness, RNFLTt: Temporal Retinal Nerve Fiber Layer Thickness, RNFLTts: Temporal Superior Retinal Nerve Fiber Layer Thickness, RNFLTti: Temporal Inferior Retinal Nerve Fiber Layer Thickness.

tomography (CT), particularly in the early stage of disease before the onset of cardinal symptoms. In some cases, it may not be easy to distinguish the tremor of IPD from essential tremor in early stage of disease [25].

From this perspective, measuring the thickness of RNFL by OCT plays an important role in the differential diagnosis of IPD. However, controversial results reported in the literature make the routine use of OCT improper. Altintas et al. [8] demonstrated a relationship between the severity of IPD and thickness of fovea using time domain OCT; however, there was no relationship between the RNFLT measurements and IPD severity. In addition, a statistically significant correlation was found between the temporal RNFLT and IPD severity in the studies of La Morgia et al. and Garcia et al. [7,14] investigating the relationship between IPD and RNFLT using OCT.

In the present study, we found RTn and RNFLTg to be thinner in the IPD group, although there was no significant thinning in the other measurements of RT. These findings are inconsistent with the findings of Altintas et al. [8]. A meta-analysis carried out by Yu et al. [26], based on the

**Table 2** Correlation between OCT findings and MMSE, H&Y, UPDRS, and duration of disease in IPD Group.

n = 25	MMSE	H&Y	UPDRS	Disease duration (months)
<b>Median (Min–Max.)</b>	28 (21–30)	1 (0–5)	24 (4–74)	48 (2–192)
<b>Pearson's correlation analysis</b>				
AL (mm)	1	0.5	0.2	0.6
CCT (µm)	0.1	0.1	0.2	0.4
IOP (mmHg)	0.2	0.9	0.6	0.6
RTc (µm)	0.3	0.5	0.6	0.6
RTn (µm)	0.5	0.8	0.9	0.9
RTt (µm)	0.8	0.8	0.8	0.7
RNFLTg (µm)	0.5	0.4	0.6	0.7
RNFLTn (µm)	0.8	0.2	0.3	0.4
RNFLTns (µm)	0.2	0.5	0.4	0.1
RNFLTts (µm)	0.3	0.2	0.3	0.5
<b>Spearman's Rho</b>				
Spherical equivalent	0.8	0.9	0.7	0.2
VA (logMAR)	0.4	0.2	0.3	1
RNFLTni	0.4	0.8	0.9	0.6
RNFLTt	0.5	0.8	0.4	0.3
RNFLTti	0.5	0.4	0.8	0.9

IPD: Idiopathic Parkinson Disease, MMSE: Mini-Mental State Examination, H&Y: Hoehn and Yahr, UPDRS: United Parkinson's Disease Rating Scale AL: Axial Length, CCT: Central Corneal Thickness, VA: Visual Acuity, RTc: Central Retinal Thickness, RTn: Nasal Retinal Thickness, RTt: Temporal Retinal Thickness, RNFLTn: Nasal Retinal Nerve Fiber Layer Thickness, RNFLTns: Nasal Superior Retinal Nerve Fiber Layer Thickness, RNFLTni: Nasal Inferior Retinal Nerve Fiber Layer Thickness, RNFLTt: Temporal Retinal Nerve Fiber Layer Thickness, RNFLTts: Temporal Superior Retinal Nerve Fiber Layer Thickness, RNFLTti: Temporal Inferior Retinal Nerve Fiber Layer Thickness.

published data from 13 articles revealed a significant decrease in the mean RNFLT, superior, inferior, and nasal and temporal quadrants. In the aforementioned study, the subgroup analysis showed that there was a significant difference of the mean RNFLT values and in the temporal quadrant, consistent with our findings.

Furthermore, in our study, although not statistically significant, the RNFLT tended to be thinner in all quadrants in the IPD patients. In consistent with the literature data [27], we found thinner RTn values in these patients, compared to the control group.

Although different studies provide controversial results, the majority of the reports show that RNFLT tends to be thinner in IPD patients. In a previous study, IPD patients were reported to have dopamine dysfunction in the retinal cells [3]. Thus, the retinal thickness measured by OCT may be an important parameter for the diagnosis of IPD as an indicator of reduced dopaminergic activity. However, further studies are needed to confirm this finding. Although the RNFLT thickness was found to be statistically significantly thinner in the IPD group in our study, we found no statistically significant correlation between the IPD severity and RNFLTg. The inability to show a statistically significant



correlation may be secondary to a lack of power due to the small sample size.

In addition, in the present study, the IOP was found to decrease in the IPD group. In the literature, glaucoma rates were found to be higher in the patients with Parkinson's disease; however, the IOP was found to be lower in the patients with IPD without glaucoma [28]. Similarly, in our study, the IOP was found to be lower in the IPD group, consistent with the literature. Nonetheless, further large-scale studies are required to investigate the cause of this phenomenon.

Additionally, several studies have been carried out on decreased VA in IPD patients [29,30]. In consistent with the findings of previous studies, we found VA to be significantly lower in the IPD group, which may be due to the thinning of RT and RNFLTg in IPD patients.

On the other hand, the major limitation of this study is the relatively small sample size in the patient group. In addition, the patient group was heterogeneous in terms of the duration, stage, and severity of the disease and the lack of correlation between the severity of disease and our findings may be due to these factors. Therefore, we believe that large-scale and long-term follow-up studies including subgroups would make valuable contributions to early diagnosis of IPD.

## Conclusions

In conclusion, OCT is a cost-effective, rapid, and non-invasive optical interferometric method generating cross-sectional images of the retina. In our study, we found lower RNFLTg, RTn, VA, and IOP scores in the IPD patients. In addition, the RNFLTg and RTn were found to be thinner in the IPD group. The thinning of the RNFLTg and RTn may have caused lower VA scores. However, the effects of retinal dopamine depletion on RT need to be investigated. In addition, we found no statistically significant correlation between the RNFLTg and RTn and severity of IPD due to the small and heterogeneous sample group. Therefore, there is a need for more comprehensive studies on a larger population, and the reason of lower IOP values in non-glaucomatous IPD patients should be evaluated in future studies.

## References

- [1] Witjas T, Kaphan E, Azulay J, Blin O, Ceccaldi M, Pouget J, et al. Nonmotor fluctuations in Parkinson's disease frequent and disabling. *Neurology* 2002;59:408–13.
- [2] Gross RE, Watts RL, Hauser RA, Bakay RA, Reichmann H, von Kummer R, et al. Intrastriatal transplantation of microcarrier-bound human retinal pigment epithelial cells versus sham surgery in patients with advanced Parkinson's disease: a double-blind, randomised, controlled trial. *Lancet Neurol* 2011;10:509–19.
- [3] Harnois C, Di Paolo T. Decreased dopamine in the retinas of patients with Parkinson's disease. *Invest Ophthalmol Vis Sci* 1990;31:2473–5.
- [4] Tian T, Zhu X-H, Liu Y-H. Potential role of retina as a biomarker for progression of Parkinson's disease. *Int J Ophthalmol* 2011;4:433.
- [5] Bodis-Wollner I, Miri S, Glazman S. Venturing into the no-man's land of the retina in Parkinson's disease. *Mov Disord* 2014;29:15–22.
- [6] Jiménez B, Ascaso FJ, Cristóbal JA, López del Val J. Development of a prediction formula of Parkinson disease severity by optical coherence tomography. *Mov Disord* 2014;29:68–74.
- [7] Garcia-Martin E, Rodriguez-Mena D, Satue M, Almarcegui C, Dolz I, Alarcia R, et al. Electrophysiology and optical coherence tomography to evaluate Parkinson disease severity electrophysiology and OCT in Parkinson. *Invest Ophthalmol Vis Sci* 2014;55:696–705.
- [8] Altıntaş Ö, Işeri P, Özkan B, Çağlar Y. Correlation between retinal morphological and functional findings and clinical severity in Parkinson's disease. *Doc Ophthalmol* 2008;116:137–46.
- [9] Inzelberg R, Ramirez JA, Nisipeanu P, Ophir A. Retinal nerve fiber layer thinning in Parkinson disease. *Vis Res* 2004;44:2793–7.
- [10] Moschos MM, Tagaris G, Markopoulos I, Margetis I, Tsapakis S, Kanakis M, et al. Morphologic changes and functional retinal impairment in patients with Parkinson disease without visual loss. *Eur J Ophthalmol* 2010;21:24–9.
- [11] Rohani M, Langroodi AS, Ghourchian S, Falavarjani KG, SoUdi R, Shahidi G. Retinal nerve changes in patients with tremor dominant and akinetic rigid Parkinson's disease. *Neurol Sci* 2013;34:689–93.
- [12] Satue M, Garcia-Martin E, Fuertes I, Otin S, Alarcia R, Herrero R, et al. Use of Fourier-domain OCT to detect retinal nerve fiber layer degeneration in Parkinson's disease patients. *Eye* 2013;27:507–14.
- [13] Kirbas S, Turkyilmaz K, Tufekci A, Durmus M. Retinal nerve fiber layer thickness in Parkinson disease. *J Neuro Ophthalmol* 2013;33:62–5.
- [14] La Morgia C, Barboni P, Rizzo G, Carbonelli M, Savini G, Scaglione C, et al. Loss of temporal retinal nerve fibers in Parkinson disease: a mitochondrial pattern? *Eur J Neurol* 2013;20:198–201.
- [15] Archibald N, Clarke M, Mosimann U, Burn D. Retinal thickness in Parkinson's disease. *Park Relat D* 2011;17:431–6.
- [16] Aaker GD, Myung JS, Ehrlich JR, Mohammed M, Henchcliffe C, Kiss S. Detection of retinal changes in Parkinson's disease with spectral-domain optical coherence tomography. *Clin Ophthalmol* 2010;4:1427–32. <https://doi.org/10.2147/OPHTH.S15136>.
- [17] Albrecht P, Müller A-K, Südmeyer M, Ferreira S, Ringelstein M, Cohn E, et al. Optical coherence tomography in Parkinsonian syndromes. *PLoS One* 2012;7, e34891.
- [18] Tsironi EE, Dastiridou A, Katsanos A, Dardiotis E, Veliki S, Patramani G, et al. Perimetric and retinal nerve fiber layer findings in patients with Parkinson's disease. *BMC Ophthalmol* 2012;12:1.
- [19] Roth NM, Saidha S, Zimmermann H, Brandt AU, Isensee J, Benkhellouf-Rutkowska A, et al. Photoreceptor layer thinning in idiopathic Parkinson's disease. *Mov Disord* 2014;29:1163–70.
- [20] Garcia-Martin E, Pueyo V, Ara J, Almarcegui C, Martin J, Pablo L, et al. Effect of optic neuritis on progressive axonal damage in multiple sclerosis patients. *Mult Scler* 2011;17:830–7.
- [21] Garcia-Martin E, Pablo LE, Herrero R, Satue M, Polo V, Larrosa JM, et al. Diagnostic ability of a linear discriminant function for spectral-domain optical coherence tomography in patients with multiple sclerosis. *Ophthalmology* 2012;119:1705–11.
- [22] Martínez A, Proupim N, Sanchez M. Retinal nerve fibre layer thickness measurements using optical coherence tomography in migraine patients. *Brit J Ophthalmol* 2008;92:1069–75.
- [23] Kesler A, Vakhapova V, Korczyn AD, Naftaliev E, Neudorfer M. Retinal thickness in patients with mild cognitive impairment and Alzheimer's disease. *Clin Neurol Neurosur* 2011;113:523–6.

- [24] Moreno-Ramos T, Benito-León J, Villarejo A, Bermejo-Pareja F. Retinal nerve fiber layer thinning in dementia associated with Parkinson's disease, dementia with lewy bodies, and Alzheimer's disease. *J Alzheimer's Dis* 2013;34:659–64.
- [25] Thenganatt MA, Louis ED. Distinguishing essential tremor from Parkinson's disease: bedside tests and laboratory evaluations. *Expert Rev Neurother* 2012;12:687–96.
- [26] Yu JG, Feng YF, Xiang Y, Huang JH, Savini G, Parisi V, et al. Retinal nerve fiber layer thickness changes in Parkinson disease: a meta-analysis. *PLoS One* 2014;9, e85718.
- [27] Mailankody P, Battu R, Khanna A, Lenka A, Yadav R, Pal PK. Optical coherence tomography as a tool to evaluate retinal changes in Parkinson's disease. *Park Relat D* 2015;21:1164–9.
- [28] Biousse V, Skibell B, Watts R, Loupe D, Drews-Botsch C, Newman N. Ophthalmologic features of Parkinson's disease. *Neurology* 2004;62:177–80.
- [29] Armstrong RA. Visual signs and symptoms of Parkinson's disease. *Clin Exp Optom* 2008;91:129–38.
- [30] Armstrong RA. Oculo-visual dysfunction in Parkinson's disease. *J Park Dis* 2015;5:715–26.