

Are MR Compatible hemoclips safe after control of hemostasis?

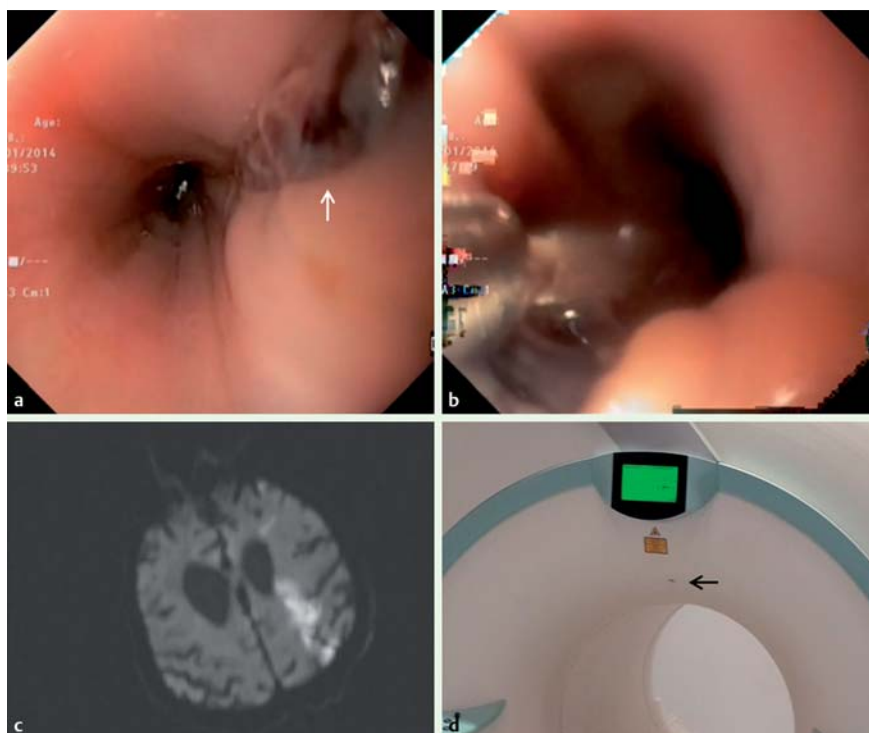


Fig. 1 An 82-year-old patient underwent hemoclip application for hemostasis, with lethal consequences at subsequent magnetic resonance imaging (MRI). **a** The linear laceration in the esophageal wall seen during upper endoscopy. **b** Hemoclip application for hemostasis. **c** Diffusion-weighted MRI section at $b = 1000 \text{ s/mm}^2$ demonstrated high signal intensity in the left parietal lobe (which has low mean apparent diffusion coefficient values – not shown), consistent with cytotoxic edema due to acute infarction. **d** A hemoclip (arrow) in the MRI scanner.

An 82-year-old man with a medical history of hypertension and cerebrovascular disease was referred to our clinic with hematemesis. Laboratory findings were: hemoglobin 8.5 g/dL (normal range $14 - 18 \text{ g/dL}$), white blood cells $16.1 \times 10^9/\text{L}$ (normal range $4 - 10 \times 10^9/\text{L}$), and platelets $74 \times 10^9/\text{L}$ (normal range $150 - 400 \times 10^9/\text{L}$). He was given a transfusion of two units of packed red blood cells.

He underwent emergency endoscopy, which revealed bright red blood in the esophagus and stomach. Below the upper esophageal sphincter, a long, deep, linear laceration with an adhering blood clot was seen in the proximal esophagus (Fig. 1a). A hemoclip (Instinct; Cook Medical Inc., Bloomington, Indiana) was applied at both edges of the laceration (Fig. 1b). He was placed on a proton pump inhibitor infusion and kept nil per os.

His hemoglobin level subsequently stabilized at 11.6 g/dL without further transfu-

sion. Six days later, he noticed decreased strength in his right hand. Brain magnetic resonance imaging (MRI) showed extensive cytotoxic edema within the parietal lobe indicating acute infarction in the left middle cerebral artery territory (Fig. 1c). During the return to his hospital room, the patient started vomiting blood. Cardiopulmonary arrest occurred as a result of the sudden massive hematemesis, and the patient died.

Endoscopic clipping devices have been used to achieve hemostasis of focal gastrointestinal bleeding [1]. Hemoclips will spontaneously slough off in approximately 3–4 weeks, but can also remain at the site of application for up to 1 year [2]. The Instinct hemoclip is a stainless steel clip that can be rotated, closed, reopened, and repositioned. It is “MR Conditional,” a safety term which indicates that the device has been demonstrated to pose no known hazards in a specified MRI environment with specified conditions of use

[3]. However, we tested a closed Instinct hemoclip in the MRI scanner and it flew instantly to the magnet (Fig. 1d).

In conclusion, it would seem from the present case that magnetically induced displacement force, torque, and vibration may cause clip migration, resulting in severe rebleeding with lethal outcome. Therefore, a high level of attention is warranted for entry to the MRI suite, even for patients who have received MR Conditional hemoclips.

Endoscopy_UCTN_Code_CPL_1AH_2AC

Competing interests: None

Mevlut Kurt¹, Emrah Posul¹, Vildan Tekelioglu², Bulent Yilmaz³, Ugur Korkmaz³, Betul Kizildag⁴

¹ Department of Gastroenterology, Abant Izzet Baysal University, Faculty of Medicine, Bolu, Turkey

² Department of Internal Medicine, Abant Izzet Baysal University, Faculty of Medicine, Bolu, Turkey

³ Department of Gastroenterology, Bolu Izzet Baysal State Hospital, Bolu, Turkey

⁴ Department of Radiology, Abant Izzet Baysal University, Faculty of Medicine, Bolu, Turkey

References

- Hwang JH, Fisher DA, Ben-Menachem T et al. The role of endoscopy in the management of acute non-variceal upper GI bleeding. *Gastrointest Endosc* 2012; 75: 1132–1138
- Technology Assessment Committee. Chuttani R, Barkun A et al. Endoscopic clip application devices. *Gastrointest Endosc* 2006; 63: 746–750
- ASTM F2503–13. Standard practice for marking medical devices and other items for safety in the magnetic resonance environment. Available from: www.astm.org/Standards/F2503.htm

Bibliography

DOI <http://dx.doi.org/10.1055/s-0034-1377542>
Endoscopy 2014; 46: E471
 © Georg Thieme Verlag KG
 Stuttgart · New York
 ISSN 0013-726X

Corresponding author

Mevlut Kurt, MD
 Department of Gastroenterology
 Faculty of Medicine
 Abant Izzet Baysal University
 PK: 14280, Golkoy
 Bolu
 Turkey
 Fax: +90-374-2534615
 dr.mevlutkurt@gmail.com