



Effects of different local haemostatic agents on facial swelling after the third molar surgery

İsmail Şener^{a*}, Murat Metin^b, Cihan Bereket^a, Mustafa Tek^c, Selim Arıcı^d, Alper Alkan^e

^a Department of Oral and Maxillofacial Surgery, Faculty of Dentistry, Ondokuz Mayıs University, Samsun, Turkey

^b Private Practice, Bursa, Turkey

^c Department of Oral and Maxillofacial Surgery, Faculty of Dentistry, Abant İzzet Baysal University, Bolu, Turkey

^d Department of Orthodontics, Faculty of Dentistry, Ondokuz Mayıs University, Samsun, Turkey

^e Department of Oral and Maxillofacial Surgery, Faculty of Dentistry, Erciyes University, Kayseri, Turkey

ARTICLE INFO

ABSTRACT

Article History

Received 21 / 11 / 2014

Accepted 24 / 12 / 2014

* Correspondence to:

İsmail Şener

Department of Oral and Maxillofacial

Surgery, Faculty of Dentistry,

Ondokuz Mayıs University,

Samsun, Turkey

e-mail: isener@omu.edu.tr

Keywords:

Gelatin sponge

Facial swelling

Local haemostatic agents

Oxidized regenerated cellulose

Point counting technique

Third molar surgery

It was aimed to investigate the effects of three different local haemostatic agents (oxidized regenerated cellulose, gelatin sponge and collagen sponge) on the facial swelling after surgical removal of impacted the third mandibular molar teeth, in this study. Sixty-six healthy patients (mean age, 21.21±3.14 years) requiring bilateral impacted third molar extractions were included in this double-blind, randomized, controlled clinical study. All teeth were removed bilaterally in the same operation by one surgeon. The left side of the mandible served as the test side for local haemostasis and the right side as the control side in all patients. After removal, the primary closure of surgical wound was provided with silk sutures, in the control side. One of the absorbable haemostatic agents, oxidized regenerated cellulose (ORC), gelatin sponge (GS) and collagen sponge (CS) was placed in the extraction cavities following gauze packing for 5 minutes to prevent bleeding and after that the wound was sutured. Data was collected regarding the operating time, mouth opening, and facial swelling. Facial swelling was measured by "point counting technique" on standard posteroanterior skull radiographs. The comparisons of differences belonging to ORC, GS and CS applications on preoperative and postoperative edema showed that the differences were not statistically significant according to analysis of variance (ANOVA) ($p>0.05$). This study has shown that the haemostatic local agents do not have any significant effect in the facial edema.

© 2015 OMU

1. Introduction

The complaint of third molar teeth constitutes the great majority of the patients consulting oral surgery clinic. The third molar teeth operation, on the other hand, can result in ache, edema, trismus and haematoma as a result of surgical trauma to the bone and soft tissues. Edema is an undesired situation which is come across after almost all third molar surgeries (Danda et al., 2010).

Several methods have been used in order to decrease or to prevent edema after impacted third molar removal in the

literature. These methods are;

a. Thermal treatments (cold and hot applications (Forsgren et al., 1985)

b. Primary and secondary wound closure (Rakprasitkul and Pairuchvej, 1997)

c. Various surgical techniques (Absi and Shepherd, 1993)

d. Laser application (Roynesdal et al., 1993)

e. Sucking drains (Brabander and Cattaneo, 1988)

f. Antibiotics (Krekmanov and Nordenram, 1986)

g. Anti-inflammatory drugs [non-steroidal anti-

inflammatory drugs (Amin and Laskin, 1983; Jackson, 1999)

h. Enzymes (Shuttee, 1962)

i. Antihistamines (Szmyd, 1956)

j. Corticosteroids (Esen et al., 1999) and

k. Haemostatic agents (Alkan et al., 2004).

By using technological improvements, some methods of objective measurements were developed (Milles et al., 1985; Pedersen and Maersk-Moller, 1985; Lewelyn et al., 1996):

a) In one dimensional registration; Composing stick (Milles et al., 1985), Face-bow (Milles et al., 1985), Impression phonograph record (Pedersen and Maersk-Moller, 1985) and Ultrasound (Schultze-Mosgau et al., 1995).

b) In two dimensional registration; Lateral and posteroanterior radiographies (Alkan et al., 2004), Frontal photographs (Milles et al., 1985; Pedersen and Maersk-Moller, 1985), Modified face-bow (Pedersen and Maersk-Moller, 1985) and Magnetic Resonance Imaging (Lewelyn et al., 1996).

c) In three dimensional registration; Stereo photographic techniques (Pedersen and Maersk-Moller, 1985; Lewelyn et al., 1996) and Computerized tomographic method (Esen et al., 1999).

Postoperative edema measuring method should be sensitive, harmless, can be repeatable and with minimal error. Among all these methods three dimensional methods were the found to be the most suitable methods for measuring edema (Rasse et al., 1991).

A local haemostatic agent and systemic tranexamic acid might be more effective in reducing post-operative bleeding and edema when used together (Gersema and Baker, 1992). In recent years, several local haemostatic agents have been used to overcome local bleeding in oral surgery. In this study, three different local haemostatic agents were used to test their effects on edema by preventing bleeding after impacted third molar removal.

2. Materials and methods

In this study the effects of three kinds of different local haemostatic agents and on the edema after impacted mandibular third molar tooth operations were investigated. In this investigation, postoperative edema and trismus were measured objectively. The gathered values were evaluated statistically.

This investigation was a double-blind, randomized, controlled clinical trial conducted in patients after extraction of an impacted mandibular third molar. Sixty-six patients, 38 female and 28 male, referred to Ondokuz Mayıs University Faculty of Dentistry Oral and Maxillofacial Surgery Clinic

for extraction of bilateral and symmetrical impacted mandibular third molars, were included in this clinical trial. Panoramic radiography was used to determine the degree of impaction and position of the impacted third molars. The ages of the patients varied between 17 and 32, with a mean age of 21.21 ± 3.14 .

The patients were informed about our investigation and the volunteers accepting to join in this study were randomly included in one of the study groups. The patients who have any kind of systemic disease or who have acute infection around the tooth were not selected for this study. Furthermore, a special attention was paid not to include patients having used any medicine during the previous week before the operation. The impacted mandibular third molars were removed bilaterally by the same surgeon in the same session in order to create equal operation conditions on both sides, under standard surgical disciplines.

Surgical approach

Inferior alveolar nerve block (1.5 ml) and buccal local (0.5 ml) anaesthesia were applied in all patients using local anaesthetic injection containing 40mg/ml articain hydrochloride and 0,006 mg/ml epinephrine hydrochloride (Ultracain® DS, Hoechst). Patients requiring additional anaesthetic dose were not included in this study. The right third mandibular impacted molars were extracted first, in all patients. Meticulous care was taken not to exert unnecessary force on soft tissues during the surgical procedure. For removal of the bony retentions, sharp round and fissure burrs of the same dimensions were used in all patients. The teeth were extracted using elevator and forceps, and by separating crown and/or roots with burr, when necessary. Sharp bone edges were smoothed and the tooth follicles were removed in all patients. After irrigating the socket with 10 ml isotonic saline, the flap was primarily closed with 3/0 silk suture in a routine fashion, in the control site. Gauze packing was placed onto the extraction socket for 5 minutes for haemostasis purposes. Bleeding coming from the soft tissues was cauterized when necessary. After sufficient haemostasis, the gauze pack was removed and one of the local haemostatic agents (ORC, GS, CS) was placed into the extraction socket and the flap was primarily closed with 3/0 silk sutures, in test sites. The duration between the beginning of mucosal incision and the completing the sutures was recorded as the operation period.

None of the patients was prescribed postoperative antibiotics. The patients were prescribed benzidamin hydrochloride mouth gargle as an antiseptic and naproxen sodium (550 mg, twice a day, during five day) as analgesic

Table 1. The comparisons of edema measuring as cm^2 and the amount of increasing number as percentage of test and control group on the 1st, 3rd and 7th pre and postoperative days.

	ORC n=22		GS n=22		CS n=22	
	Test X±SD	Control X±SD	Test X±SD	Control X±SD	Test X±SD	Control X±SD
Preop. measured value (cm^2)	9.02±2.56	8.63±2.41	9.30±2.09	8.51±2.13	9.58±2.76	9.34±2.87
Postop. 1. day (cm^2)	11.21±2.76	10.82±2.90	12.34±2.93	11.37±3.30	12.13±3.22	11.14±3.29
Postop. 3. day (cm^2)	10.80±2.47	10.36±3.20	12.83±2.45	11.53±2.56	12.08±3.53	10.88±2.91
Postop. 7. day (cm^2)	9.90±2.60	9.35±2.29	10.59±2.47	9.89±2.34	10.32±2.89	9.75±2.88

ORC: Oxidized regenerated cellulose; GS: Gelatin sponge; CS: Collagen sponge; X: Mean; SD: Standart deviation

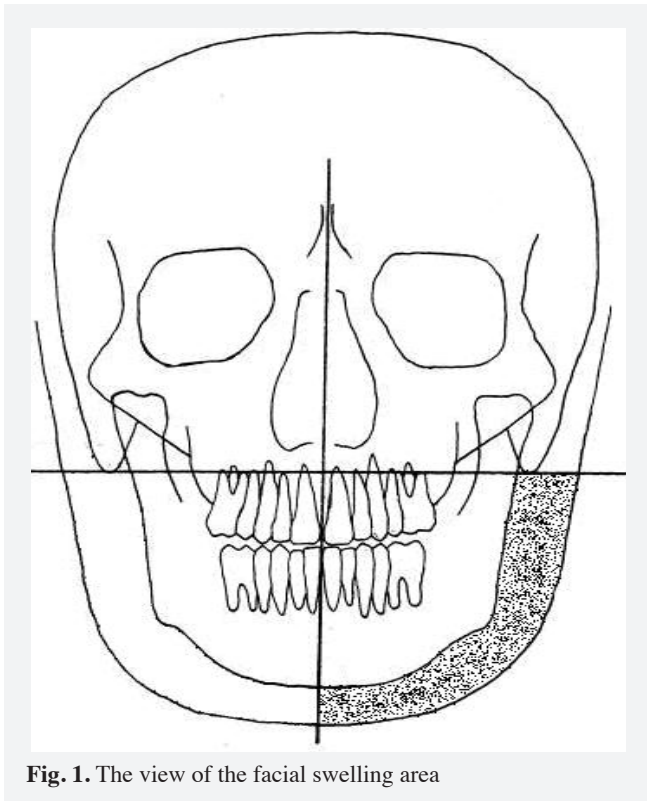


Fig. 1. The view of the facial swelling area

for postoperative pain control. Also they were advised not to use any other medicine or physiotherapy except for those we recommended.

Edema evaluation

To measure edema after the surgical extraction of the third mandibular molar teeth, posteroanterior skull radiographs taken before and after the operation on the 1st, 3rd and 7th days were evaluated. The lines passing the midsagittal plane, and those passing through both of the mastoid processes on horizontal plane were drawn as well as the lateral bony and soft tissue margins of the mandible on the posteroanterior radiographs (Fig. 1). The area between the bone and the soft tissue margins was measured by point counting technique in square centimeters, which was repeated at one week intervals for 3 times and arithmetic mean values were calculated (Fig. 2).



Fig. 2. The grid used for the point counting technique. A point counting grid with 6 mm between the plusses was superimposed over the drawing to assess the projection area of the mandible.

Trismus evaluation

To measure the postoperative trismus, maximum interincisal distance between the incisal edges of the central teeth was measured in millimeters, for three times and the mean value were recorded, with the help of composing stick by having the patient open his/her mouth as much as possible. The measurements were recorded in the patients' follow-up form, as the trismus values of preoperative, 1st, 3rd and 7th postoperative days.

For statistical evaluation, the differences in values between the right and left sides were evaluated using analysis of variance (ANOVA) at the 95% level of significance ($p < 0.05$).

3. Results

A total of 132 third molar surgeries were performed on 66 patients, including 22 patients in each group, composing ORC, GS and CS groups. The average difference in operation duration between the control and test groups were not found to be statistically significant ($p < 0.05$). As for the edema values, in comparison with control side values, it was observed that the patients in CS group reached preoperative measurement values in a very short time; on the contrary, the values of the patients in GS group were the reverse. However, the differences were not found to be significant ($p > 0.05$).

As for the edema values in the test side, again, it was observed that the patients in CS group reached preoperative values in a very short time; while, the patients in GS group were the reverse. However, it was not found to be statistically significant ($p > 0.05$). Based on the gathered statistics, the differences between ORC, GS and CS applications were not found to be statistically significant in comparison with the control values, and the differences in the quantity of edema occurred on 1st, 3rd and 7th postoperative days were not found to be statistically significant ($p > 0.05$). The comparisons of differences belonging to ORC, GS and CS applications on preoperative and postoperative edema showed that the differences were not statistically significant ($p > 0.05$). The values for comparison of the test and control groups, their edema measurements as square centimeters and their edema increase as percentage on preoperative and 1st, 3rd and 7th postoperative days were shown in Table 1. The average maximum mouth opening values on preoperative and 1st, 3rd, 7th postoperative days belonging to the test groups are shown in Table 2. Trismus was detected as the most severe in the GS group on the first postoperative day, and the least severe on the 7th day in the CS group, but the results were not found to be statistically significant ($p > 0.05$).

Table 2. Average maximum interincisal distance measuring values in ORC, GS and CS group, on preoperative and 1st, 3rd and 7th postoperative days.

	ORC n=22	GS n=22	CS n=22
	X±SD	X±SD	X±SD
Preop. max. mouth opening (mm)	39.05±4.23	42.18±7.56	43.41±5.90
Postop. 1st day (mm)	23.32±6.94	23.32±7.69	25.68±6.07
Postop. 3rd day (mm)	25.36±9.28	24.86±8.39	29.68±7.25
Postop. 7th day (mm)	31.23±8.23	32.68±7.27	36.09±7.20

ORC: Oxidized regenerated cellulose; GS: Gelatin sponge; CS: Collagen sponge; X: Mean; SD: Standart deviation

The use of haemostatic local agents does not produce statistically significant differences in the edema and the trismus following the exodontia of 3rd mandibular molars.

4. Discussion

Some complications can occur if the impacted mandibular and maxillary third molar teeth remain in the mouth. These complications can be listed as; crowding in dentition, pericoronitis, periodontitis, focal infection, neuralgia typed ache, chronic headache, resorption in adjacent tooth root, caries on the distal surface of the adjacent tooth, follicular cyst or tumor, the weakness of the mandible caused by the impacted tooth in the mandible. In one of these circumstances, the extraction may become necessary (Stathopoulos et al., 2011). During the surgical extraction of the impacted mandibular third molar teeth, especially when removing bone, some undesired complications like edema, trismus and pain occur after the surgical trauma which constitutes the main reason for edema (Sisk et al., 1986; Senghore and Harris, 1999). Because of the topographic structure of head and neck, it is rather difficult to measure the amount of edema in this area. The amount of edema may differ according to the position of tooth and the experience of surgeon, and from one patient to another (Sisk et al., 1986). In this study, we observed that edema and trismus were both correlated with total operation duration.

No matter how little the trauma to the tissues for the surgical extraction of the impacted mandibular third molar teeth, around 90 percent of patients feel the postoperative ache and need analgesic drugs (Jackson et al., 1989). For this reason, the patients were prescribed naproxen sodium as a postoperative analgesic agent in the present study.

In the literature, several different techniques have been used to measure post-operative swelling. Because of the fact that one dimensional techniques like palpation and inspection do not give sensitive and clear results, and that the three dimensional techniques are difficult to apply and finance, posteroanterior radiographs were chosen for evaluation of the edema by two dimensional measurements in the present study. In this study, we measured the facial swelling on the posteroanterior skull radiographs by using point counting technique. This method has disadvantages such as inability of performing a volumetric measurement but this is a very suitable measurement technique using on posteroanterior radiograph besides minimal postoperative irradiation (Alkan et al., 2004).

Several methods have been used in order to decrease or prevent edema after impacted third molar removal in the literature. Low-dose methylprednisolone is known to lessen the postoperative edema in 42%, by measuring facial contour on postoperative 1st, 2nd, 3rd, 4th and 7th days (Milles and Desjardins, 1993). Dubois et al. (1982), reported that primary wound closure caused much more complications than those of secondary after impacted third molar surgery. As all the third molars to be removed were completely impacted, and flaps were closed primarily with sutures with no significant postoperative complications, but no comparisons were made between the primary and secondary closure techniques in

our study. Roynesdal et al., (1993) reported that the laser application on the swollen area after the extraction of the impacted mandibular third molar tooth did not provide any benefit. Whereas, Aras and Güngörmüş (2010) demonstrated that extra oral Low Level Laser therapy (LLL) is more effective than intra oral LLLT for the reduction of postoperative trismus and swelling after extraction of the lower third molar. Brabander and Cattoneo (1998) studied the effect of sucking drains and secondary covering on the postoperative edema, trismus and ache 2 and 7 days after the surgery to compare with the control group. They found that facial edema, ache and trismus were lesser in the group where drain was used. Monaco et al. (1999) argued that there was no difference between using daily oral 2 gr amoxicillin for 5 postoperative days and using no antibiotics in terms of fever, ache, edema and alveolar alveolitis. Kaczmarzyk et al. (2007) found no statistically significant differences in postoperative inflammatory complications in patients during the first and second days postsurgery. Poeschl et al. (2004) study show that specific postoperative oral prophylactic antibiotic treatment after the removal of lower third molars does not contribute to a better wound healing, less pain, or increased mouth opening and could not prevent the cases of inflammatory problems after surgery, respectively, and therefore is not recommended for routine use. In contrast to this, Arteagoitia et al. (2005) found that Amoxicillin/clavulanic acid is efficacious in reducing the incidence of inflammatory complications following third molar extraction but should not be prescribed in all cases. Although there were many studies that reduce or not affect the use of pre and postoperative and antibiotics in the literature regarding complications of postoperative, none of our patients in our study were prescribed antibiotics pre and postoperatively. It was showed that hyaluronidase enzyme reduces postoperative trismus, edema and ache (Shuttee, 1962). It was found that there was not a clear effect of antihistamines on preventing postoperative edema (Szmyd, 1956). It was declared that indomethacin lessened the ache and edema after the impacted mandibular third molar tooth operation, with no effect on trismus (Amin and Laskin, 1983). Gallardo et al. (1990) declared that glucomethacin has a minimal effect on ache occurring postoperative impacted mandibular third molar tooth operation, without any effect on trismus and edema. There are few studies in the literature that investigated post-operative bleeding after impacted third molar surgery. One of these by Alkan et al. (2004) planned to minimize the bleeding intraoperatively by using a haemostatic agent, ORC. They found that local haemostatic application with Surgicel® into the socket of the extracted 3rd molar did not change the amount of edema significantly in comparison with controls. They reported that minimizing the postoperative bleeding by using local haemostatic agents did not have any effect on edema. In this study, we investigated the effects of different local haemostatic agents on facial swelling after third molar surgery. Since the results of the present study show that the three haemostatic agents, ORC, GS, and CS were not found to be effective to reduce the postoperative edema, it can be concluded that the facial swelling is not solely due to the postoperative bleeding.

REFERENCES

- Absi, E.G., Shepherd, J.P., 1993. A comparison of morbidity following the removal of lower third molars by the lingual split and surgical bur methods. *Int. J. Oral. Maxillofac. Surg.* 22, 149-153. doi:10.1016/S0901-5027(05)80240-1.
- Alkan, A., Metin, M., Arici, S., Sener, I., 2004. A prospective randomised cross-over study of the effect of local haemostasis after third molar surgery on facial swelling: an exploratory trial. *Br. Dent. J.* 197, 42-44. doi:10.1038/sj.bdj.4811421.
- Amin, M.M., Laskin, D.M., 1983. Prophylactic use of indomethacin for prevention of postsurgical complications after removal of impacted third molars. *Oral. Surg. Oral. Med. Oral. Pathol.* 55, 448-451.
- Aras, M.H., Güngörmüş, M., 2010. Placebo-controlled randomized clinical trial of the effect two different low-level laser therapies (LLLT)--intraoral and extraoral on trismus and facial swelling following surgical extraction of the lower third molar. *Lasers. Med. Sci.* 25, 641-645. doi:10.1007/s10103-009-0684-1.
- Arteagoitia, I., Diez, A., Barbier, L., Santamaría, G., Santamaría, J., 2005. Efficacy of amoxicillin/clavulanic acid in preventing infectious and inflammatory complications following impacted mandibular third molar extraction. *Oral. Surg. Oral. Med. Oral. Pathol. Oral. Radiol. Endod.* 100, 11-18. doi:10.1016/j.tripleo.2005.03.025.
- Brabander, E.C., Cattaneo, G., 1988. The effect of surgical drain together with a secondary closure technique on postoperative trismus, swelling and pain after mandibular third molar surgery. *Int. J. Oral. Maxillofac. Surg.* 17, 119-121.
- Danda, A.K., Krishna, Tatiparthi, M., Narayanan, V., Siddareddi A., 2010. Influence of primary and secondary closure of surgical wound after impacted mandibular third molar removal on postoperative pain and swelling a comparative and split mouth study. *J. Oral. Maxillofac. Surg.* 68, 309-312. doi:10.1016/j.joms.2009.04.060.
- Dubois, D.D., Pizer, M.E., Chinnis, R.J., 1982. Comparison of primary and secondary closure techniques after removal of impacted mandibular third molars. *J. Oral. Maxillofac. Surg.* 40, 631-634. doi:10.1016/0278-2391(82)90111-2.
- Esen, E., Taşar, F., Akhan, O., 1999. Determination of the anti-inflammatory effects of methylprednisolone on the sequelae of third molar surgery. *J. Oral. Maxillofac. Surg.* 57, 1201-1206. doi:10.1016/S0278-2391(99)90486-X.
- Forsgren, H., Heimdahl, A., Johansson, B., Krekmanov, L., 1985. Effect of application of cold dressings on the postoperative course in oral surgery. *Int. J. Oral. Maxillofac. Surg.* 14, 223-228.
- Gallardo, F., Carstens, M., Ayarza, M., 1990. Analgesic and antiinflammatory effects of glucamethacin (a nonsteroidal antiinflammatory analgesic) after the removal of impacted third molars. *Oral. Surg. Oral. Med. Oral. Pathol.* 69, 157-160.
- Gersema, L., Baker, K., 1992. Use of corticosteroids in oral surgery. *J. Oral. Maxillofac. Surg.* 50, 270-277. doi:10.1016/0278-2391(92)90325-T
- Jackson, D.L., Moore, P.A., Hargreaves, K.M., 1989. Preoperative nonsteroidal anti-inflammatory medication for the prevention of postoperative dental pain. *J. Am. Dent. Assoc.* 119, 641-647.
- Jackson, D.L., 1999. Determination of the anti-inflammatory effects of methylprednisolone on the sequelae of third molar surgery (discussion). *J. Oral. Maxillofac. Surg.* 57, 1206-1208. doi:10.1016/S0278-2391(99)90486-X.
- Kaczmarzyk, T., Wichlinski, J., Stypulkowska, J., Zaleska, M., Panas, M., Woron, J., 2007. Single-dose and multi-dose clindamycin therapy fails to demonstrate efficacy in preventing infectious and inflammatory complications in third molar surgery. *Int. J. Oral. Maxillofac. Surg.* 36, 417-422. doi:10.1016/j.ijom.2006.12.003.
- Krekmanov, L., Nordenram, A., 1986. Postoperative complications after surgical removal of mandibular third molars. Effects of penicillin V and chlorhexidine. *Int. J. Oral. Maxillofac. Surg.* 15, 25-29.
- Lewelyn, J., Ryan, M., Santosh, C., 1996. The use of magnetic resonance imaging to assess swelling after the removal of third molar teeth. *Br. J. Oral. Maxillofac. Surg.* 34, 419-423.
- Milles, M., Desjardins, P.J., Pawel, H.E., 1985. The facial plethysmograph: a new instrument to measure facial swelling volumetrically. *J. Oral. Maxillofac. Surg.* 43, 346-352. doi:10.1016/0278-2391(85)90255-1.
- Milles, M., Desjardins, P.J., 1993. Reduction of postoperative facial swelling by low-dose methylprednisolone: an experimental study. *J. Oral. Maxillofac. Surg.* 51, 987-991.
- Monaco, G., Staffolani, C., Gatto, M.R., Checchi, L., 1999. Antibiotic therapy in impacted third molar surgery. *Eur. J. Oral. Sci.* 107, 437-441.
- Pedersen, A., Maersk-Møller, O., 1985. Volumetric determination of extraoral swelling from stereophotographs. A method study in the buccal area. *Int. J. Oral. Surg.* 14, 229-234.
- Poeschl, P.W., Eckel, D., Poeschl, E., 2004. Postoperative prophylactic antibiotic treatment in third molar surgery--a necessity? *J. Oral. Maxillofac. Surg.* 62, 3-8. doi:10.1016/j.joms.2003.05.004.
- Rakprasitkul, S., Pairuchvej, V., 1997. Mandibular third molar surgery with primary closure and tube drain. *Int. J. Oral. Maxillofac. Surg.* 26, 187-190.
- Rasse, M., Forkert, G., Waldhausl P., 1991. Stereophotogrammetry of facial soft tissue. *Int. J. Oral. Maxillofac. Surg.* 20, 163-166.
- Roynesdal, A.K., Bjørnland, T., Barkvoll, P., Haanaes, H.R., 1993. The effect of soft-laser application on postoperative pain and swelling. A double-blind, crossover study. *Int. J. Oral. Maxillofac. Surg.* 22, 242-245.
- Schultze-Mosgau, S., Schmelzeisen, R., Frolich, J.C., Schmele, H., 1995. Use of ibuprofen and methylprednisolone for the prevention of pain and swelling after removal of impacted third molars. *J. Oral. Maxillofac. Surg.* 53, 2-7. doi:10.1016/0278-2391(95)90486-7.
- Senghore, N., Harris, M., 1999. The effect of tranexamic acid (cyclokapron) on blood loss after third molar extraction under a day case general anaesthetic. *Br. Dent. J.* 186, 634-636.
- Shuttee, T.S., 1962. Hyaluronidase in relief of postoperative trismus, swelling, and pain. Separate injection in 150 oral surgical procedures. *Oral. Surg. Oral. Med. Oral. Pathol.* 15, 115-120.
- Sisk, A.L., Hammer, W.B., Shelton, D.W., Joy, E.D., 1986. Complications following removal of impacted third molars: the role of the experience of the surgeon. *J. Oral. Maxillofac. Surg.* 44, 855-859. doi:10.1016/0278-2391(86)90221-1.
- Stathopoulos, P., Mezitis, M., Kappatos, C., Titsinides, S., Stylogianni, E., 2011. Cysts and tumors associated with impacted third molars: is prophylactic removal justified? *J. Oral. Maxillofac. Surg.* 69, 405-408. doi: 10.1016/j.joms.2010.05.025.
- Szmyd, L., 1956. A clinical evaluation of an antihistaminic preparation in oral surgery. *Oral. Surg. Oral. Med. Oral. Pathol.* 9, 928-931.