



PEDIATRIC UROLOGY CASE REPORTS

ISSN 2148-2969

<http://www.pediatricurologycasereports.com>

Buccal mucosal graft urethroplasty for the treatment of fistula after failed hypospadias repair: A case report

Omer Faruk Yagli¹, Ali Gokkaya², Jehat Kizilkan³

¹Department of Urology, Tuzla State Hospital, Istanbul, Turkey

²Faculty of Medicine, Department of Plastic Surgery, Abant Izzet Baysal University - Bolu, Turkey

ABSTRACT

Complication rates are gradually decreasing with new surgical techniques used in hypospadias repair. Even under the best conditions, various complications can develop after hypospadias surgery. The most common complication is urethrocutaneous fistula formation. In this case report, the fistula developed after failed hypospadias repair was successfully repaired with a buccal mucosal graft.

Key Words: Hypospadias; fistula; buccal mucosal graft.

Copyright © 2018 [pediatricurologycasereports.com](http://www.pediatricurologycasereports.com)

Corresponding Author: Dr. Omer Faruk Yagli
Department of Urology, Tuzla State Hospital, Istanbul,
Turkey

E-mail: ofyagli@yahoo.com

Accepted for publication: 05 January 2018

Introduction

Complication rates of hypospadias surgery are gradually decreasing due to newly developed surgical techniques and care products [1]. Even at the best circumstances complications may develop after hypospadias surgery. Most common complication of hypospadias repair is fistula formation [2,3].

Fistula formation depends on many factors. Factors such as edema, infection and hematoma might disrupt the vascularization and healing of newly formed urethra. During urination meathal stenosis and distal urethral obstructions causes high urethral pressures.

Due to this high pressure urethrocutaneous fistulas might form, just as it did in our case.

Flap necrosis, urethral stenosis and various types of disfigurations can be seen other than fistula.

During the treatment of urethral fistulas, buccal mucosal grafts, full-thickness skin (genital and extra-genital), bladder mucosa, colonic mucosa, tunica vaginalis and grafts tissue-engineered grafts can be used [4-6]. The approach to the fistula depends on the size of the fistula, the localization, and the length of time that the fistula occurs after surgery. Urethral fistulas are generally detected after catheter removal and in the first 6 months [7]. In this case report, we aim to discuss a case of urinary difficulty due to a totally closed distal urethral meatus and advanced degree of fistula stenosis 10 years after hypospadias surgery.

Case report

19 year old male patient; presented to our clinic as having urinary difficulty. During physical examination, urination was observed from a 3 Fr wide-stenotic fistula and 1 cm inferior to external mea [Fig. 1A]. Ultrasonography examination showed an increase in trabecular formation in the bladder. Distal urethral mea was totally obstructed [Fig. 1B]. In his medical history, we learnt that urinary difficulty started 10 years ago after hypospadias surgery and circumcision was performed.

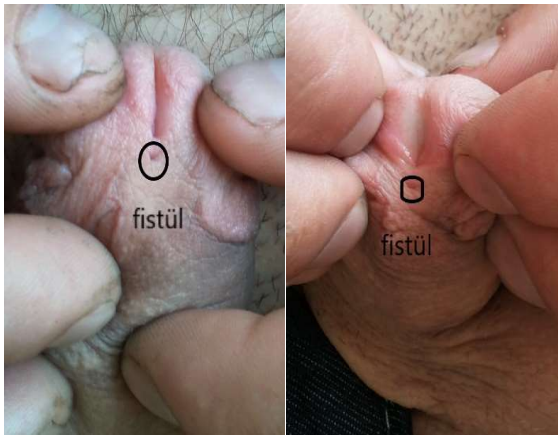


Fig. 1. A) Advanced degree narrow fistula opening. B) Totally obstructed urethral mea and narrow fistula opening.

Due to total obstruction of urethral mea and advanced degree of fistular stenosis, in order to obtain adequate urethral width, distal urethroplasty with buccal mucosal graft was planned preoperatively.

Under general anesthesia approximately 2x2 cm wide mucosal graft was harvested from left buccal mucosa. After removal of the fistula tract, the distal urethral ventral portion was incised up to the mea and the urethra was widened. Then graft tissue was sutured to ventral urethra and graft edges were tabularized to form a new mea [Fig. 2]. The

patient whose catheter was removed after 1 week postoperatively, had no urethral stenosis or fistula formation in the 2-year follow up [Fig. 3A,B].

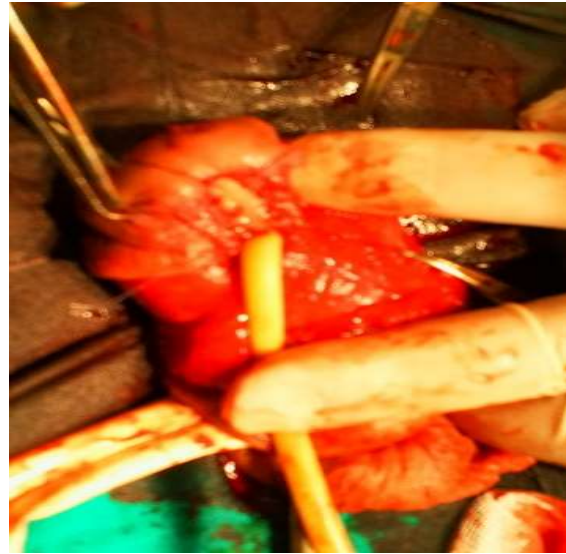


Fig. 2. Buccal mucosal graft application.

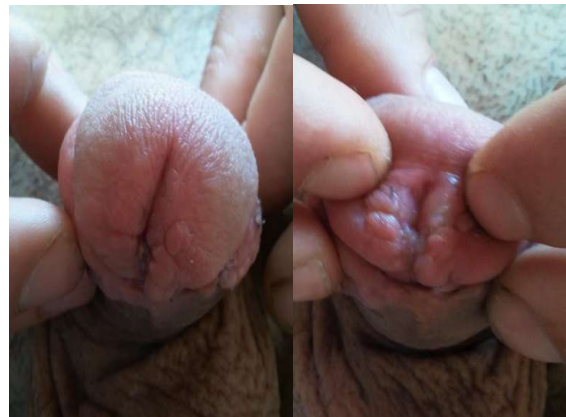

Fig. 3A, B. The appearance of the distal urethral meatus after operation.

Discussion

Localization and size of urethral fistula determines the method of surgery [2]. Especially during the repair fistulas localized on glandular sulcus, mobilization issues and lack of surrounding tissue renders standard surgical methods unusable. At these patients

opening of distal urethra from fistula, fistula excision and re-tubularization of urethra is needed [3]. In order to prevent stenosis and fistula formation after re-tubularization, newly formed urethral calibration has to be wide. There are various surgical methods developed in order to obtain adequate width. Among mucosal grafts, successful use of buccal mucosa in the repair of urethral fistula is a proven phenomenon and was first reported in 1894 [8]. This wet epithelium is relatively easy to obtain and to regulate, and has very good immunity. Therefore, today, the preferred donor site for repair of buccal mucosa urethral strictures [9]. Additionally, extensive capillary network of the thick buccal mucosa epithelium provides rapid neovascularization [6,9,10]. However, there are some morbidities, such as perioral numbness, difficulty in opening the mouth and less commonly, dry mouth, and long term complications such as scarring [11]. In this case with the buccal mucosal graft urethroplasty method, distal urethral calibration was kept wide and the possibility of recurrent fistula and stenosis was reduced. In conclusion, in cases where fistulas formed after distal hypospadias surgery and has narrow urethral calibration which need primary hypospadias surgery again, buccal mucosal graft and urethroplasty method is safe and feasible method.

Compliance with ethical statements

Conflicts of Interest: None.

Financial disclosure: None.

Consent: All photos were taken with parental consent.

References

- [1]Ozturk H. Buccal mucosa urethroplasty in a reoperative and reconstructive challenge hypospadias: a case report. *Ped Urol Case Rep*. 2014;1(1):1-5.
- [2]Hadidi AT. Fistula repair. In: Hadidi AT, Azmy AF, editors. *Hypospadias Surgery*. Heidelberg: Springer; (2004). p. 277–82.
- [3]Shanberg AM, Sanderson K, Duel B. Re-operative hypospadias repair using the Snodgrass incised plate urethroplasty. *BJU Int*. 2001; 87(6): 544-47.
- [4]Ahmed S, Cough DC. Buccal mucosal graft for secondary hypospadias repair and urethral replacement. *Br J Urol*. 1997; 80(2): 328-30.
- [5]Ehrlich RM, Alter G. Split-thickness skin urethroplasty and tunica vaginalis flaps for failed hypospadias repairs. *J Urol*. 1996; 155(1): 131-34.
- [6]Mangera A, Chapple C. Management of anterior urethral stricture: an evidence-based approach. *Curr Opin Urol*. 2010; 20(6):453- 58.
- [7]Wood HM, Kay R, Angermeier KW. Timing of the presentation of urethrocutaneous fistulas after hypospadias repair in pediatric patients. *J Urol*. 2008;180(4 Suppl):1753-6.
- [8]Sievert KD, Seibold J, Schultheiss D, et al. Reconstructive urology in the change, from its beginning to the close future. *Urologe A*. 2006; 45 (Suppl 4):52-8.
- [9]Bhargava S, Chapple CR. Buccal mucosal urethroplasty: is it the new gold standard? *BJU Int*. 2004; 93(9):1191-93.
- [10]Dubey D, Vijjan V, Kapoor R, Srivastava A, Mandhani A, Kumar A, Ansari MS. Dorsal onlay buccal mucosa versus penile skin flap urethroplasty for anterior urethral strictures: results from a randomized prospective trial. *J Urol*. 2007;178(6):2466-69.
- [11]Wood DN, Allen SE, Andrich DE, Greenwell TJ, Mundy AR. The morbidity of

buccal mucosal graft harvest for urethroplasty and the effect of nonclosure of the graft harvest site on postoperative pain. *J Urol*. 2004;172(2):580-3.

