



Computed Tomography Findings of Massive Air Embolism Caused by Cavitory Lesion

Hamza Özer^{id}, Samet Genez^{id}

Department of Radiology, Bolu Abant İzzet Baysal University Faculty of Medicine, Bolu, Turkey

A 23-year-old male patient had tetraplegia owing to a spinal cord injury after a traffic accident. In the intensive care unit, a tracheostomy was performed on the patient, who developed massive hemoptysis during follow-up. The patient was taken for urgent bronchoscopic evaluation by the thoracic surgeon, but no intervention could be carried out due to massive bleeding. A computed tomography angiography (CTA) was performed to determine the etiology of the bleeding. The chest CTA revealed that the heart's four chambers and the arterial and venous vascular systems, including the portal venous system, were completely filled with air (Figures 1a, 1b, and 1c). Additionally, cavitory lesions, consolidation areas, and tree-in-bud appearance were observed in both lung parenchymas, and pneumothorax was detected on the right side. A clotted appearance was observed in the right superior lobar and right main bronchus (Movie). The CTA findings were thought to have developed secondary to a bronchovascular fistula following the rupture of the right apex cavitory lesion and rapid blood-gas exchange with the check valve mechanism of the tracheostomy. The bronchovascular fistula is believed to be related to both the pulmonary artery and venous system due to rapid air embolism and bleeding. Hemoptysis is believed to have originated from the pulmonary arterial system, subsequently leading to air embolism through the pulmonary venous system. Previous literature has documented cases of air embolisms resulting from bronchovascular fistulas and hemoptysis resulting from bronchoarterial fistulas.^{1,2} Additionally, there have been reports of air embolisms arising from cavitory lesions of the lungs.³ Massive air embolisms have been reported in cases of gunshot wounds.⁴ We present our case as a rare example of the rapid development of both hemoptysis and embolism resulting from the rupture of a cavitory lesion.

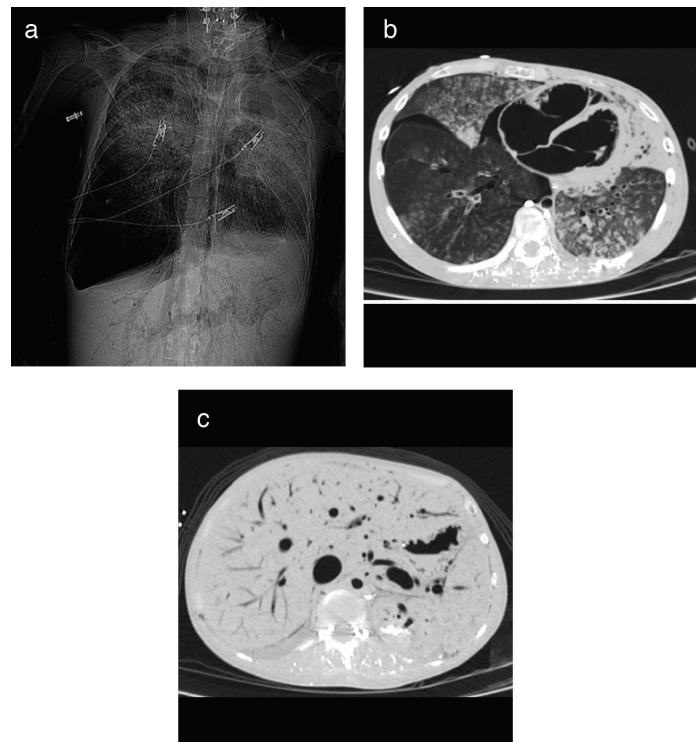


FIG. 1a, 1b, and 1c. CT scanogram (a) and axial images on chest CTA show that the four chambers of the heart (b), arterial and venous vascular systems, including the portal venous system (c), are completely filled with air.

Movie: Axial plane thorax CTA sections show that all vascular structures are filled with air. It is also observed that the contrast agent administered through the central venous catheter is distributed to the thoracolumbar venous plexuses via the azygos vein. Finally, pneumothorax accompanying the cavitory lesion that lost its distension at the apex of the right lobe was observed. A clotted appearance was noted in the right superior lobar and in the right main bronchus.

CTA, computed tomography angiography



Corresponding author: Hamza Özer, Department of Radiology, Bolu Abant İzzet Baysal University Faculty of Medicine, Bolu, Turkey
e-mail: hozermd@gmail.com

Received: December 21, 2022 Accepted: February 04, 2023 Available Online Date: March 08, 2023 • DOI: 10.4274/balkanmedj.galenos.2023.2022-12-60

Available at www.balkanmedicaljournal.org

ORCID iDs of the authors: H.Ö. 0000-0003-3210-4544; S.G. 0000-0002-1484-4496.

Cite this article as:

Özer H, Genez S. Computed Tomography Findings of Massive Air Embolism Caused by Cavitory Lesion. *Balkan Med J.*; 2023; 40(2):145-6.

Copyright@Author(s) - Available online at <http://balkanmedicaljournal.org/>

Informed consent: Informed consent was obtained from the patient's relative.

Author Contributions: Concept- H.Ö.; Design- H.Ö.; Supervision- H.Ö.; Data Collection or Processing- S.G.; Literature Search- S.G.; Writing- S.G.

Conflict of Interest: No conflict of interest was declared by the authors.

REFERENCES

1. Saita K, Kariya T, Ezaka M, Nakao T, Kin N. Bronchovenous Fistula During Adult Cardiac Surgery: A Case Report. *AA Pract.* 2020;14:e01321. [\[CrossRef\]](#)
2. Newcomer J, Weber J, Galuppo R, Gabriel G, Diab C. Pulmonary artery-bronchus fistula treated with coil embolization. *Radiol Case Rep.* 2022;17:2652-2656. [\[CrossRef\]](#)
3. Lin C, Barrio GA, Hurwitz LM, Kranz PG. Cerebral Air Embolism from Angioinvasive Cavitary Aspergillosis. *Case Rep Neurol Med.* 2014;2014:1-4. [\[CrossRef\]](#)
4. Zeynalova A, Sanli DET, Agar EH, Yildirim D, Tuzuner F. CT Findings of the Massive Air Embolism in a Case with Thoracic Gunshot Wound: A Special Case Report as if a Whole Body Pneumo- Angiography was Performed. *Curr Med Imaging.* 2022;18:1253-1256. [\[CrossRef\]](#)