



EDİTÖRE MEKTUP / LETTER TO THE EDITOR

Retroperitoneally located first collision tumor of extra-gastrointestinal stromal tumor and inflamatuar myofibroblastic tumor

Retroperitoneal yerleşimli ekstra-gastrointestinal stromal tümör ve inflamatuar myofibroblastik tümör birlikteliğinde ilk kollizyon tümörü

Hesna Müzeyyen Astarçıl¹, Nur Tunç²

¹Lokman Hekim University Department of Pathology, Ankara, Turkey

²Bolu Abant İzzet Baysal University Department of Pathology, Bolu, Turkey

Cukurova Medical Journal 2020;45(4):1868-1871

To the Editor,

A collision tumor is the coexistence of two histologically different tumors in the same organ or close anatomical location. Although collision tumors have been reported in many organs, they are very rare in retroperitoneum. ¹. In the literature, two cases of collision tumors: liposarcoma with pancreatic adenocarcinoma ² and monoclonal plasma cell

infiltration with schwannoma ³ have been reported in the retroperitoneum (Table 1). To the best of our knowledge, it has not been reported in the literature a collision tumor arising from the association of extra-gastrointestinal stromal tumor (E-GIST) and inflammatory myofibroblastic tumor (IMT). In this study, we present the first case of a collision tumor associated with retroperitoneal E-GIST and IMT in a 60-year-old female patient.

Table 1 Cases of collision tumors seen in the retroperitoneum in the literature

| | Age/Sex | Collision Tumors | Tumor Size | References |
|---|---------|---|------------|------------|
| 1 | 64/M | Retroperitoneal liposarcoma and pancreatic adenocarcinoma | 35 cm | (2) |
| 2 | 54/M | Retroperitoneal schwannoma and monoclonal plasma cell infiltration | 5.2 cm | (3) |
| 3 | 60/F | Retroperitoneal extra-gastrointestinal stromal tumor and inflammatory myofibroblastic tumor | 9 cm | Our case |

A 60-year-old female patient presented with rapid weight loss in 2 months. Abdomen computed tomography (CT) imaging showed a well circumscribed solid lesion of 71x77x96 mm in the paracaval area of the right retroperitoneum that may be consistent with a malignant mesenchymal tumor (Figure 1). Retroperitoneal mass excision was performed.

Macroscopic examination revealed a smooth surfaced mass of 9x7x6,5 cm. The cross-sectional

face of the sliced material was heterogeneous, bleeding in places, and having a hard elastic consistency. Histopathological examination revealed a tumoral formation with cells of epitheloid and atypical spindle morphology with large hyperchromatic vesicular nuclei, clear vacuolar cytoplasm with prominent nuclear pleomorphism and eosinophilic nucleoli. (Figure 2a). Mitotic activity was visible in 35/50 high power fields (HPF). Immunohistochemical staining showed focal

Yazışma Adresi/Address for Correspondence: Dr. Nur Tunç, Bolu Abant İzzet Baysal University, Department of Pathology, Bolu, Turkey E-mail: tncnur@gmail.com

Geliş tarihi/Received: 07.09.2020 Kabul tarihi/Accepted: 09.10.2020 Çevrimiçi yayın/Published online: 30.12.2020

membranous and cytoplasmic staining with CD117 (Figure 2b).

Vimentin showed strong diffuse positivity. CD34, DOG1 and smooth muscle actin (SMA) were negative. A well-seperated second tumor consisting hypocellular collagenous stromal proliferation of fibroblasts and myofibroblasts forming short fascicles with mild atypia was detected (Figure 3a).

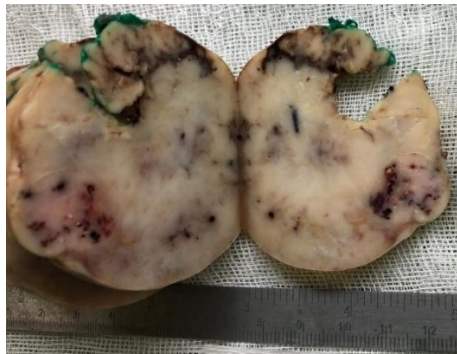

Figure 1. Macroscopic view of material: Heterogeneous cross-sectional area, hemorrhagic mass, hard elastic consistency

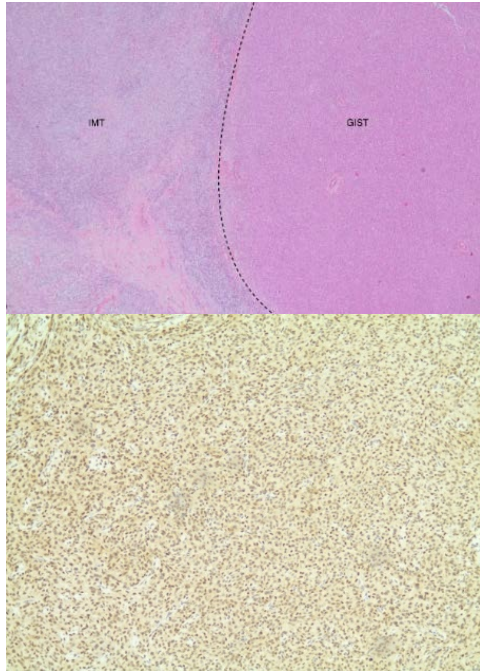


Figure 2. Histopathological examination of gastrointestinal stromal tumor areas a. GIST and IMT association b. Immunohistochemically CD117 positivity in GIST

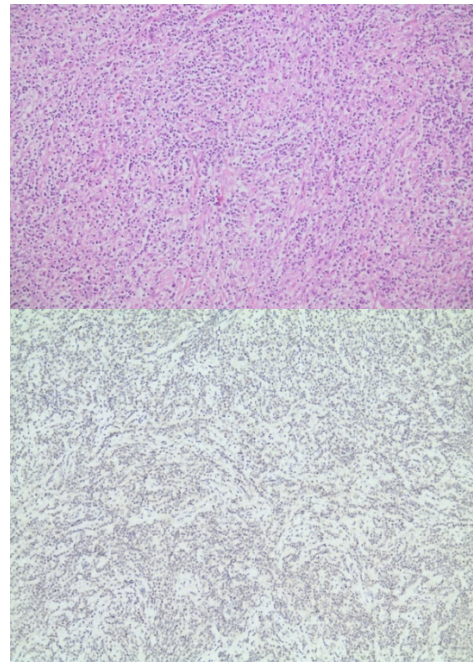


Figure 3. Histologic examination of inflammatory myofibroblastic tumor areas a. Mononuclear inflammatory cell infiltration of the short fascicles of myofibroblastic cells b. ALK negativity in tumor cells

Dense mononuclear inflammatory cell infiltration consisting of lymphocytes and plasma cells scattered between these fascicles was noted. Immunohistochemical staining was negative with CD117, CD34, DOG1 and ALK. Desmin showed positive staining in focal areas while SMA was negative (Figure 3b).

The case was reported as retroperitoneal E-GIST and IMT. Retroperitoneal tumors are very rare. However, retroperitoneal collision tumor has been reported in two cases in the literature^{2,3}. To the best of our knowledge, it has not been reported in the literature a collision tumor arising from the association of extra-gastrointestinal stromal tumor (E-GIST) and inflammatory myofibroblastic tumor (IMT). Therefore, this case is the first collision tumor with retroperitoneal localization of E-GIST and IMT.

Gastrointestinal stromal tumors are usually located in the gastrointestinal tract, most commonly in the stomach and small intestine, showing KIT or PDGFRA mutations. However, there are some GISTs located outside of the gastrointestinal tract. These tumors have been identified as extra-

gastrointestinal stromal tumors or E-GIST. Very few cases of retroperitoneal E-GIST have been reported and the clinicalopathological correlation and long-term follow-up data of these tumors are insufficient⁴. The incidence of E-GISTs is very rare and occurs in less than 1% of all gastrointestinal malignancies, accounting for about 10% of all GIST cases⁵. GISTs are generally defined as KIT (CD117) positive mesenchymal neoplasms and this information is the basis of the drugs used in routine. Cajal cells are the KIT positive spindle cell population, especially around the myenteric plexus. KIT receptor activating mutations account for 60-70% of all GISTs⁶. Miettinen et al.⁴ analyzed comprehensive immunohistochemical and molecular genetic features in 112 retroperitoneal GIST cases. According to this study, CD117 showed strong positive staining in most tumor cells in 106/112 (95%) cases. Six of the DOG1 positive cases (81/87, 93%) included CD117 negative cases. CD34 was positive in more than 25% of tumor cells in 53/86 cases (62%). SMA was positive in more than 50% tumor cells in 26/84 cases (31%). In another study by Miettinen et al.⁷ on 1840 GIST cases, in extra-gastrointestinal stromal tumors DOG1 was positive in 117/128 cases (91.4%) and CD117 was positive in 119/128 cases (93.0%). Lower rates of positivity were obtained from E-GISTs located outside of the primary gastrointestinal tract than the GISTs. In our study, while focal membranous and cytoplasmic staining was observed with CD117; DOG1, CD34 and SMA were negative.

IMTs are rare neoplasms. Most of the cases are located in the lung. Among the extrapulmonary IMTs, retroperitoneal IMTs are rare, although they are most commonly seen in the bladder⁸ in the genitourinary system⁹. Coffin et al.¹⁰ reported that only 4 retroperitoneal IMTs were there in the largest series of 84 cases with extrapulmonary IMT.

Extrapulmonary IMTs are more common in adult women. Patients usually present with nonspecific symptoms¹¹. IMTs usually stain with SMA, desmin and cytokeratin. Cytoplasmic reactivity of ALK protein occurs in approximately 50% of IMTs¹². Therefore, ALK positivity is helpful in the diagnosis of IMT, but its negativity does not exclude the diagnosis of IMT. In another study by Coffin et al.¹³, cytoplasmic ALK reactivity was observed in 31/55 cases and no staining was observed in 24 cases. In the study of Marino-Enriquez et al.¹², ALC cytoplasmic reactivity was observed in 2/11 cases. While desmin was positive in 10/11 cases, focal reactivity in SMA

was reported in 4 cases, including desmin negative cases. EMA showed negative staining. In our study, staining with ALK was not observed. Desmin was positive in focal areas, while SMA was negative.

We report a collision tumor located in the retroperitoneal region. To the best of our knowledge, this case is the first reported retroperitoneal collision tumor of E-GIST and IMT.

Yazar Katkıları: Çalışma konsepti/Taşarımı: HMA, NT; Veri toplama: NT; Veri analizi ve yorumlama: NT; Yazı taslağı: NT; İçerigin eleştirilme: HMA, NT; Son onay ve sorumluluk: HMA, NT; Teknik ve malzeme desteği: HMA, NT; Süpervizyon: HMA, NT; Fon sağlama (mevcut ise): yok.

Hakem Değerlendirmesi: Dış bağımsız.

Çıkar Çatışması: Yazarlar çıkar çatışması beyan etmemişlerdir.

Finansal Destek: Yazarlar finansal destek beyan etmemişlerdir.

Author Contributions: Concept/Design : HMA, NT; Data acquisition: NT; Data analysis and interpretation: NT; Drafting manuscript: NT; Critical revision of manuscript: HMA, NT; Final approval and accountability: HMA, NT; Technical or material support: HMA, NT; Supervision: HMA, NT; Securing funding (if available): n/a.

Peer-review: Externally peer-reviewed.

Conflict of Interest: Authors declared no conflict of interest.

Financial Disclosure: Authors declared no financial support

REFERENCES

1. Shin HC, Gu MJ, Kim SW, Kim JW, Choi JH. Coexistence of gastrointestinal stromal tumor and inflammatory myofibroblastic tumor of the stomach presenting as a collision tumor: first case report and literature review. *Diagn Pathol.* 2015;10:181.
2. Buchner D, Hieggelke L, Löser H, Bruns CJ, Quaas A, Ghadimi MPH. First reported case of a collision tumor composed of pancreatic adenocarcinoma and retroperitoneal liposarcoma: a case report. *BMC Cancer.* 2018;18:1243-.
3. Damasena IL, Carey-Smith R. Retroperitoneal schwannoma with monoclonal plasma cell infiltration. *Int J Surg Pathol.* 2012;21:635-8.
4. Miettinen M, Felisiak-Golabek A, Wang Z, Inaguma S, Lasota J. GIST manifesting as a retroperitoneal tumor: clinicopathologic immunohistochemical, and molecular genetic study of 112 cases. *Am J Surg Pathol.* 2017;41:577-85.
5. Laroia ST, Yadav T, Rastogi A, Sarin S. Malignant retroperitoneal extra-gastrointestinal stromal tumor: a unique entity. *World J oncol.* 2016;7:45-50.
6. Miettinen M, Lasota J. Histopathology of gastrointestinal stromal tumor. *J Surg Oncol.* 2011;104:865-73.
7. Miettinen M, Wang ZF, Lasota J. DOG1 antibody in the differential diagnosis of gastrointestinal stromal tumors: a study of 1840 cases. *Am J Surg Pathol.* 2009;33:1401-8.
8. Ryu KH, Im CM, Kim MK, Kwon D, Park K, Ryu SB et al. Inflammatory myofibroblastic tumor of the kidney misdiagnosed as renal cell carcinoma. *J Korean Med Sci.* 2010;25:330-2.

9. Koirala R, Shakya VC, Agrawal CS, Khaniya S, Pandey SR, Adhikary S et al. Retroperitoneal inflammatory myofibroblastic tumor. *Am J Surg*. 2010;199:e17-9.
10. Coffin CM, Watterson J, Priest JR, Dehner LP. Extrapulmonary inflammatory myofibroblastic tumor (inflammatory pseudotumor). A clinicopathologic and immunohistochemical study of 84 cases. *Am J Surg Pathol*. 1995;19:859-72.
11. Attili SVS, Chandra CR, Hemant DK, Bapsy PP, RamaRao C, Anupama G. Retroperitoneal inflammatory myofibroblastic tumor. *World J Surg Oncol*. 2005;3:66.
12. Marino-Enriquez A, Wang WL, Roy A, Lopez Terada D, Lazar AJF, Fletcher CDM et al. Epithelioid inflammatory myofibroblastic sarcoma: An aggressive intra-abdominal variant of inflammatory myofibroblastic tumor with nuclear membrane or perinuclear ALK. *Am J Surg Pathol*. 2011;35:135-44.
13. Coffin CM, Hornick JL, Fletcher CD. Inflammatory myofibroblastic tumor: comparison of clinicopathologic, histologic, and immunohistochemical features including ALK expression in atypical and aggressive cases. *Am J Surg Pathol*. 2007;31:509-20.