

Polymorphic ventricular tachycardia (Torsades de pointes) due to licorice root tea

Meyan kökü çayına bağlı olarak gelişen polimorf ventrikül taşikardisi (Torsades de pointes)

Serkan Öztürk, M.D., Kayıhan Karaman, M.D.,# Mustafa Çetin, M.D.,# Alim Erdem, M.D.

Department of Cardiology, Abant İzzet Baysal University Faculty of Medicine, Bolu;

#Department of Cardiology, Kahramanmaraş Public Hospital, Kahramanmaraş

Summary– Longed QT syndromes are cardiac repolarization disorders characterized by longed QT intervals on ECG. This electrophysiological abnormality may lead to syncope or sudden cardiac death due to rapid, polymorphic ventricular tachycardia (VT). Licorice root (Glycyrrhizin glabra root) contains Glycyrrhizin, sterols and many flavones. Glycyrrhizin may have effects on cardiac repolarization and depolarization through the autonomic nervous system. We present a case of polymorphic VT (torsades de pointes) secondary to drinking 5-6 glasses of licorice root tea for constipation for 2 days prior to admission to emergency department. Licorice root consumption should be taken into account in all patients admitted to the hospital for cardiac arrhythmia. It may cause cardiac arrhythmia when consumed regularly and in excessive amounts.

Özet– Uzamış QT sendromları EKG’de uzamış QT aralıkları ile tanınan kardiyak repolarizasyon bozukluklarıdır. Bu elektrofizyolojik anormallik hızlı, polimorf ventrikül taşikardisine (VT) bağlı senkop veya ani kardiyak ölümlere de neden olabilir. Meyan kökü (Glikrizin glabra kökü) glikrizin, steroller ve çok sayıda flavonlar içerir. Glikrizinin otonom sinir sistemi aracılığıyla kardiyak repolarizasyon ve depolarizasyon üzerine etkileri olabilir. Bu yazıda, hastaneye yatıştan önce 2 gün boyunca kabızlık tedavisi için 5-6 bardak meyan kökü çayı içen ve polimorf VT (torsades de pointes) nedeniyle acil servise kabul edilen bir olgu sunuldu. Meyan kökü tüketimi kardiyak aritmi nedeniyle hastaneye başvuran hastalarda göz önüne alınmalı ve aşırı miktarda tüketildiğinde bir kardiyak aritmiye neden olabileceği düşünülmelidir.

Longed QT syndromes (LQTS) are cardiac repolarization disorders characterized by prolonged QT intervals on ECG. This electrophysiological abnormality may lead to syncope or sudden cardiac death due to rapid, polymorphic ventricular tachycardia (VT). Acquired LQTS type are more common and occur as a complication of treatment with certain drugs or toxic reactions. Detection of this clinical syndrome is necessary because its treatment differs from the treatments used in many types of VT and because the elimination of the causative agent, (antiarrhythmic drugs) or the circumstance (other toxic actions) is crucial.^[1]

We present a case of polymorphic VT (torsades de pointes - TdP) admitted to the emergency department as a result of drinking 5-6 glasses of licorice root (LR) tea for constipation.

CASE REPORT

A 59-year-old woman arrived to our emergency department by ambulance on September 4, 2010. Resuscitation was started immediately as the woman had polymorphic VT. Following return of normal sinus rhythm after resuscitation, polymorphic VT reoccurred. The patient was admitted to the intensive care unit after receiving several electrical shocks. The patient received repeated electrical shocks in coronary

Abbreviations:

LR	Licorice root
MI	Myocardial infarction
LQTS	Longed QT syndromes
TdP	Torsades de pointes
VT	Ventricular tachycardia

Received: June 04, 2012 Accepted: August 25, 2012

Correspondence: Dr. Serkan Öztürk, Abant İzzet Baysal Üniversitesi Tıp Fakültesi, Kardiyoloji Anabilim Dalı, 14280 Gököy, Bolu.

Tel: +90 374 - 253 46 56 e-mail: drserkan69@hotmail.com

© 2013 Turkish Society of Cardiology



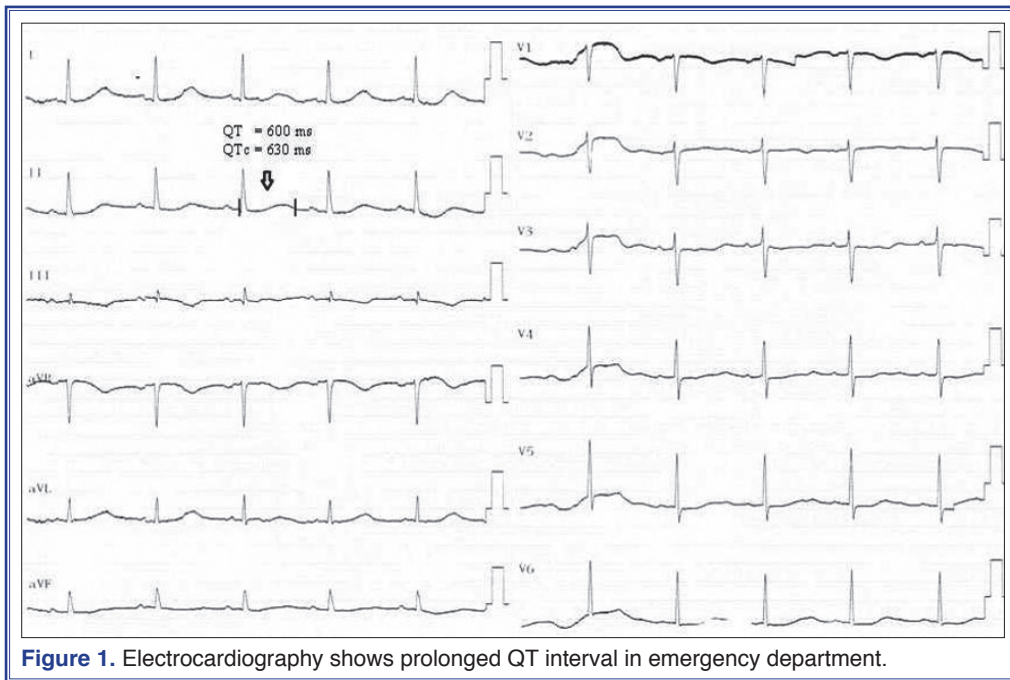


Figure 1. Electrocardiography shows prolonged QT interval in emergency department.

intensive care unit where she was monitored. Her ECG revealed prolonged QT interval (QT 580 msn, QTc 600 msn) (Fig. 1). Laboratory examinations showed a serum potassium (K^+) of 3.7 mmol/L, glucose of 155 mg/dl, and normal sodium, magnesium, and cardiac enzymes (CK 140 U/L, CK-MB 22 U/L, Troponin T 0.01). These values did not increase during monitoring. In subsequent tests, K^+ value was 4.2 mmol/L, but the patient was observed to have TdP attacks during monitoring and thus high rate pacing was performed for the control of TdP attacks (Fig. 2). Normal sinus rhythm was observed during subsequent monitoring.

Her past medical history included diabetes and a minor myocardial infarction (MI) in 2004. She had no history of sudden cardiac death or genetic disease in her family. She was taking metformin and diameprid for diabetes. Her coronary angiography demonstrated a completely occluded right coronary artery with retrograde filling. The left anterior descending artery LAD and circumflex artery were observed to be normal. Invasive intervention was deemed unnecessary because the right coronary artery occlusion was thought to be chronic. Her echocardiography showed a mild septal hypertrophy and left ventricular diastolic dysfunction with a left ventricular EF was 60%. Her history revealed that the patient had been drinking a glass of licorice tea on a daily basis and that she had

5-6 glasses of licorice tea for constipation for 2 days before admission to hospital. All electrolyte values (K^+ 3.7 mEq) and cardiac enzymes were normal in her follow-up examinations. The patient was stabilized on the 4th day and was continually monitored. On hospital day 8, NSR was observed in her ECG and QT interval went back to normal (Fig. 3). The patient was stabilized and discharged from hospital with advice to discontinue LR tea consumption.

DISCUSSION

Licorice root is a common plant in the southern regions of Turkey. Glycyrrhizin glabra root contains glycyrrhizin (50 times sweeter than sugar), sterols




Figure 2. Torsades de pointes attack during monitoring in coronary intensive care unit.

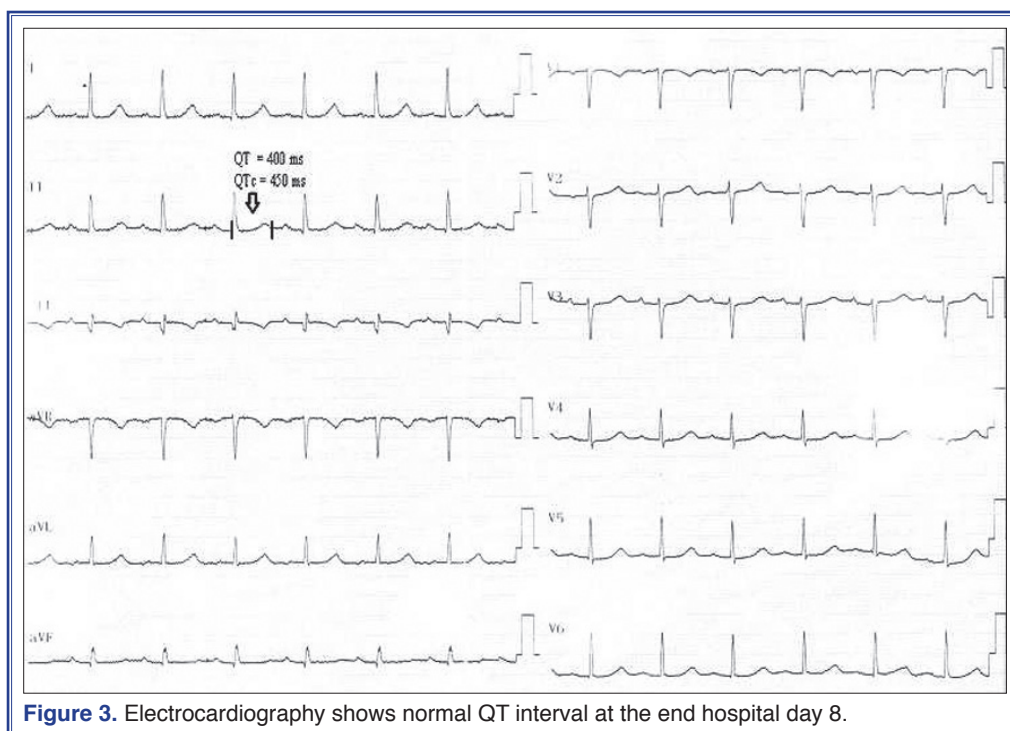


Figure 3. Electrocardiography shows normal QT interval at the end hospital day 8.

and many flavones (Liquiritin, liquiritigenin, licorice etc.).^[2] LR is a plant that may affect the endocrine system. People use LR tea for different reasons including: supportive care for common colds, flu, angina, hypertension, bowel spasms and constipation.^[3-5] Licorice extract may induce a syndrome presenting with hypertension, hypokalemia, metabolic alkalosis, low plasma renin activity, and low plasma aldosterone levels.^[6] Cases of cardiac arrhythmia and reversible dilated cardiomyopathy as a result of licorice root intoxication have been reported.^[3] Glycyrrhizin may have effects on cardiac repolarization and depolarization through the autonomic nervous system. Liquiritigenin, which is a component of licorice, is a strong inhibitor of K^+ ion channels, and different pharmacological effects of licorice may play a role in the said inhibition. Licorice may affect cardiac repolarization.^[2]

However, in these cases, toxic effects of LR have been associated with hypokalemia. In our case, unlike other cases, hypokalemia was not detected during admission. It has been shown that isoliquiritigenin (an ingredient of licorice) in LR inhibits potassium channels.^[2] In the present case, the thought was that LR prolonged the repolarization period and QT interval by affecting cardiac ion channels. A potassium level of 3.7 and a potassium level of 4.2 in TdP suggest that LR may have an effect on cardiac repolarization

through different mechanisms. Today, LR has been used in various curative herbal products. Moreover, LR tea has been commonly used as a cooling beverage during summer time. As a result, it has been observed that LR may cause cardiac arrhythmia without hypokalemia. In our case, right coronary artery occlusion was thought to be chronic and was treated medically without invasive intervention. ECG findings were fully improved after follow-up.

Previous studies showed that the rare variations in genes responsible for congenital arrhythmia syndromes are frequent in acquired LQTS and TdP.^[7,8] Napolitano et al.^[8] demonstrated that some cases of drug-induced QT prolongation may depend on a genetic substrate. Crotti et al.^[9] showed that K897T polymorphism is associated with an increased risk of TdP developing in the subacute phase of MI. Their findings support the concept that the electrical remodeling may unmask a genetic substrate predisposing to a time-limited development of life-threatening arrhythmias during the acute phase of MI. In this case, we could not investigate genetic substrate. This is the main limitation of this study. In addition, this patient had no history of sudden cardiac death or genetic disease in her family. We thought that genetic screening should be performed to exclude the presence of an LQTS disease-causing mutation.

According to prior literature, licorice should be taken into account in patients presenting to the emergency department with cardiac arrhythmia and hypokalemia.^[5,6] However, the present case shows that cardiac arrhythmia may develop without hypokalemia when licorice root is consumed regularly and in excessive amounts. As a result, getting a detailed history is very important in those admitted to the hospital for acquired QT syndrome. Licorice root consumption should be taken into account in all patients presenting to the hospital for cardiac arrhythmia, and it may cause cardiac arrhythmia when consumed regularly and in excessive amounts.

Conflict-of-interest issues regarding the authorship or article: None declared.

REFERENCES

- Schwartz PJ. The long QT syndrome. *Curr Probl Cardiol* 1997;22:297-351. [\[CrossRef\]](#)
- Noguchi C, Yang J, Sakamoto K, Maeda R, Takahashi K, Takasugi H, et al. Inhibitory effects of isoliquiritigenin and licorice extract on voltage-dependent K(+) currents in H9c2 cells. *J Pharmacol Sci* 2008;108:439-45. [\[CrossRef\]](#)
- Crean AM, Abdel-Rahman SE, Greenwood JP. A sweet tooth as the root cause of cardiac arrest. *Can J Cardiol* 2009;25:357-8. [\[CrossRef\]](#)
- Tancevski I, Eller P, Spiegel M, Kirchmair R, Patsch JR. Images in cardiovascular medicine. Malicious licorice. *Circulation* 2008;117:299. [\[CrossRef\]](#)
- Zheng A, Moritani T. Effect of the combination of ginseng, oriental bezoar and glycyrrhiza on autonomic nervous activity as evaluated by power spectral analysis of HRV and cardiac depolarization-repolarization process. *J Nutr Sci Vitaminol (Tokyo)* 2008;54:148-53. [\[CrossRef\]](#)
- Farese RV Jr, Biglieri EG, Shackleton CH, Irony I, Gomez-Fontes R. Licorice-induced hypermineralocorticoidism. *N Engl J Med* 1991;325:1223-7. [\[CrossRef\]](#)
- Ramirez AH, Shaffer CM, Delaney JT, Sexton DP, Levy SE, Rieder MJ, et al. Novel rare variants in congenital cardiac arrhythmia genes are frequent in drug-induced torsades de pointes. *Pharmacogenomics J* 2012 May 15. [\[CrossRef\]](#)
- Napolitano C, Schwartz PJ, Brown AM, Ronchetti E, Bianchi L, Pinnavaia A, et al. Evidence for a cardiac ion channel mutation underlying drug-induced QT prolongation and life-threatening arrhythmias. *J Cardiovasc Electrophysiol* 2000;11:691-6. [\[CrossRef\]](#)
- Crotti L, Hu D, Barajas-Martinez H, De Ferrari GM, Oliva A, Insolia R, et al. Torsades de pointes following acute myocardial infarction: evidence for a deadly link with a common genetic variant. *Heart Rhythm* 2012;9:1104-12. [\[CrossRef\]](#)

Key words: Glycyrrhiza/adverse effects; syndrome; hyperkalemia/etiology; long QT syndrome/complications/diagnosis; plants, medicinal; tachycardia, ventricular.

Anahtar sözcükler: Glikrizinin/yan etki; sendrom; hiperkalemi/etoloji; uzamış QT sendromu/komplikasyon/tanı; bitki, tıbbi; ventrikül taşikardisi.