

MAXILLARY FIRST PREMOLARS WITH THREE ROOT CANALS: TWO CASE REPORTS*

Üç Kanallı Maksiller Birinci Premolar Dişler: İki Olgu Bildirisi

Zeliha UĞUR¹, Kerem Engin AKPINAR², Demet ALTUNBAŞ²

Received: 13/02/2017

Accepted: 11/06/2017

ABSTRACT

It is very important that the dentists have sufficient information about possible variations in the expected root canal configurations in order to achieve success in endodontic treatment. In addition to having adequate knowledge on the variations of the root canal anatomy, periapical radiographs from different angles, careful examination of the pulp chamber floor, and use of dental operation microscope during the procedure are also important factors that contribute to the diagnosis of the additional roots and canals. The aims of this article are to present the diagnostic approach and root canal treatments of two maxillary first premolar teeth with three canals in two patients.

ÖZ

Endodontik tedavide başarının sağlanmasında hekimin beklenen kök kanal konfigürasyonlarındaki olası varyasyonlar hakkında yeterli bilgiye sahip olması büyük bir önem taşımaktadır. İlave kök ve kanalların teşhisinde kök kanal anatomisinin varyasyonları hakkında yeterli bilgiye sahip olmanın yanı sıra, farklı açılardan alınan periapikal radyografiler; pulpa odası tabanının dikkatle incelenmesi ve işlem sırasında dental operasyon mikroskopunun kullanımı da ilave kök ve kanalların tanı ve tedavi sürecinde değerlendirilmesi gereken önemli etkenlerdir. Bu makalenin amacı, iki hastada saptanan üç kanallı üst çene 1. küçük azı dişlerinin tanı sürecini ve kök kanalı tedavilerinde izlenen yaklaşımı sunmaktır.

Keywords: Root canals; variation; premolar tooth; endodontic treatment; anatomy

Anahtar kelimeler: Kök kanalı; varyasyon; küçük azı dişi; endodontik tedavi; anatomi

*One of these cases was presented as a poster at the 13th International Scientific Congress of the Turkish Endodontic Society which was held at Kapadokya, Turkey, May 26-29, 2016.

¹ Department of Endodontics Faculty of Dentistry Abant İzzet Baysal University

² Department of Endodontics Faculty of Dentistry Cumhuriyet University



Introduction

The root canal system can present different anatomical variations. Those that go unnoticed can cause failures, particularly in the root canal treatment of teeth with pulp necrosis. Clinician should therefore possess necessary knowledge concerning the normal root canal anatomy, morphology and most importantly, be ready to deal with frequent variations. All of these factors are essential for predictable success in endodontic treatment (1),.

Various studies have investigated the differences in the external and internal anatomy of maxillary first premolars (2-4). In a Turkish sample, Kartal *et al.* (5) compared the frequencies of maxillary premolar teeth having one, two or three canals and roots. Authors reported that 8.66% of the premolars had one, 89.64% had two, and 1.66% had three root canals. In terms of root number, 37.31%, of the maxillary first premolars was found to have one, 61.32% to have two, and 1.33% to have three roots. Three-rooted maxillary premolars are occasionally referred to as small molars or as radicular because of their anatomical similarity to maxillary molars (6). This variation causes additional challenge in access cavity design, localization, refining and forming of endodontic therapy procedures (7). Clinicians should consider extra roots and canals to prevent endodontic infections and related symptoms in patients (8). The aim of this case report is to present a rare anatomical variation of maxillary first premolars characterized by having two roots and canals buccally, and one root and canal palatally.

Case Reports

Case 1

A 20 years old male was referred to Cumhuriyet University, Faculty of Dentistry, Department of Endodontics. Patient's medical history was non-contributory. His main complaint was the spontaneous pain on the left side of his upper jaw. Clinical and radiographic examination revealed a deep disto-occlusal carious lesion in left maxillary first premolar. The tooth was not sensitive to percussion and exhibited normal mobility. Radiographic appearance of the periapical region was normal. Based on these findings, a diagnosis of symptomatic irreversible pulpitis was made (Figure 1). Endodontic access cavity was prepared after the injection of local anesthesia and

rubber dam isolation. During the inspection of the pulp chamber floor, a second canal orifice was seen in the buccal section of the tooth. Positions of the three canal orifices were as follows: one mesiobuccal, one distobuccal and one palatinal. The working lengths of three root canals were determined by using Raypex 5 (VDW, Munich, Germany) apex locator, and checked with a radiograph (Figure 2). Canals were instrumented using Twisted File rotary system (TF; SybronEndo, Orange, CA, USA). Patency was achieved in all the canals and was maintained with a 10 K-file (DentsplyMaillefer, Ballaigues, Switzerland). 2.5% sodium hypochlorite (NaOCl) solution was used as the main irrigant during biomechanical preparation. Root canal filling was completed by using the cold lateral compaction method with AH Plus (Dentsply DeTrey, Konstanz, Germany) sealer and gutta-percha (Diadent Group International, Chungcheongbuk-do, Korea). The root canal treatment was completed in a single-visit appointment (Figure 3). The tooth was later restored with composite resin (3M, St. Paul, MN, USA).

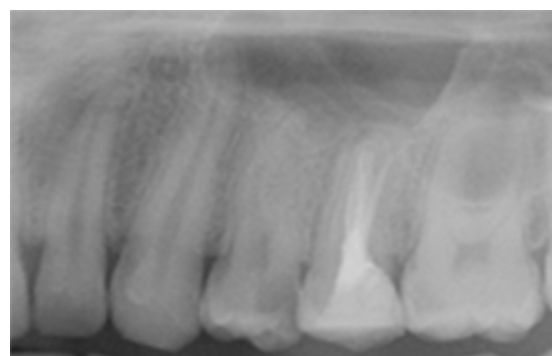


Figure 1. Periapical radiograph, showing the complex root morphology of the maxillary first premolar suggesting the existence of three root canals.

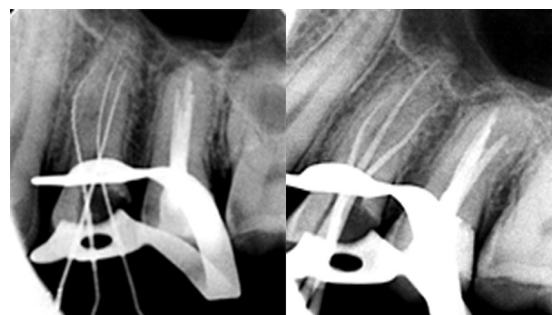


Figure 2. Radiographical confirmation of three root canals and determination of the working lengths.

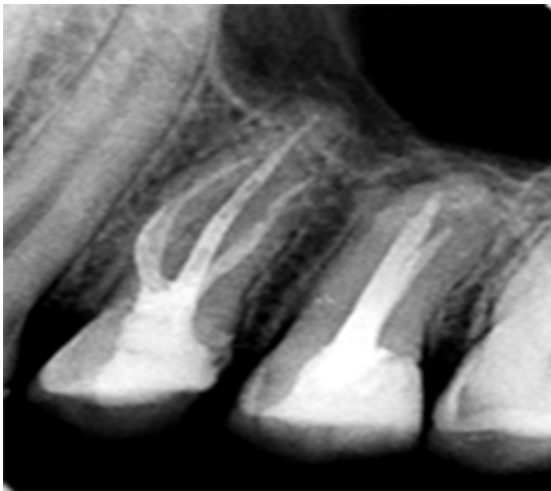

Figure 3. Periapical radiograph following the obturation of the three root canals.

Case 2

A 25 years old male patient was referred to the same institution for the treatment of his maxillary right premolar tooth. Patient's medical history was non-contributory. Intraoral examination showed a deep disto-occlusal carious lesion. No sensitivity to percussion was observed. No periapical lesion was found in the radiographic examination (Figure 4). Based on these findings, a diagnosis of symptomatic irreversible pulpitis was made. After the injection of local anesthesia and rubber dam isolation, endodontic access cavity was prepared.

The inspection of the pulp chamber floor revealed the presence of three separate root canal orifices: one mesiobuccal, one distobuccal and one palatinal. Canals were instrumented with the TF after determining their working lengths with Raypex 5 apex locator (Figure 5). Biomechanical preparation was done using %2.5 NaOCl solution as the main irrigant. Root canal filling was completed by cold lateral compaction method using AH Plus (Dentsply DeTrey, Konstanz, Germany) sealer and gutta-percha (Diadent Group International, Chungcheongbuk-do, Korea). The root canal therapy was completed in a single-visit appointment (Figure 6). The tooth was then restored with composite resin (3M, St. Paul, MN, USA).

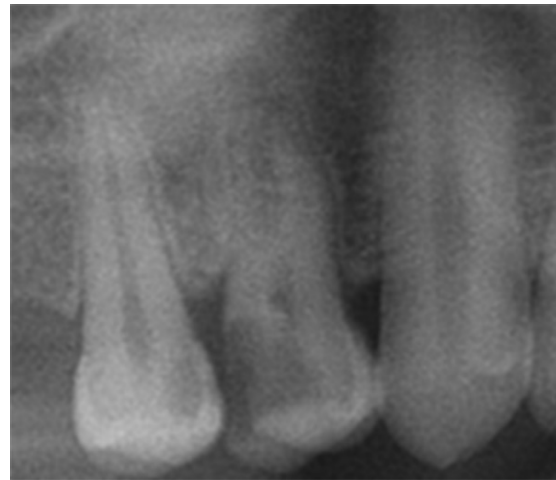

Figure 4. Periapical radiograph, showing the complex root morphology of the maxillary first premolar suggesting the existence of three root canals.

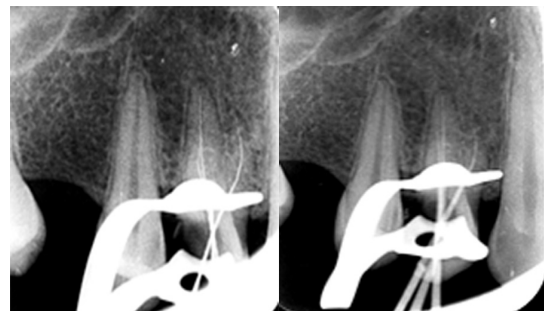

Figure 5. Radiographical confirmation of the three root canals and determination of the working lengths.

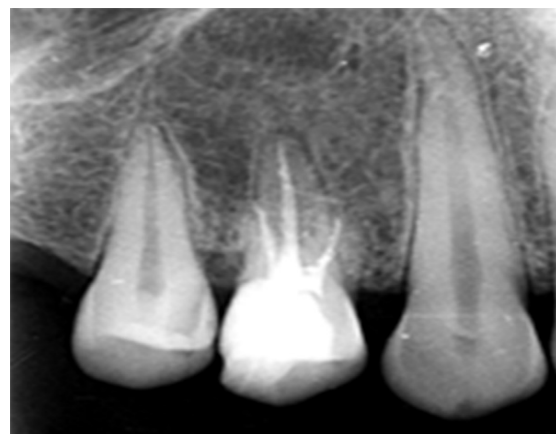


Figure 6. Periapical radiograph following the obturation of the three root canals.

Discussion

The anatomical variations of the teeth are very important in endodontics in terms of diagnosis, treatment planning and prognosis. In the present case reports, three roots and canals, which is an anatomical variation in of maxillary first premolar teeth, were shown in two different patients. Several studies regarding the presence of three roots and canals in maxillary first premolar teeth are available in the literature (9-11). In studies conducted on the Turkish population, Bulut *et al.* (12) reported that the incidence of three roots and canals in maxillary first premolar teeth was 1% while Ok *et al.* (13) reported the same incidence as 1.2%. Cleaning of the root canal system is important to achieve success in endodontic treatment. Magnifying glasses and the radiographs from different angles can be used during endodontic procedures to detect anatomical variations. However, they may not provide complete information about the canals as the resulting images are 2-dimensional. With the recent development of CBCT and its use in endodontic therapy, it is now possible to easily identify canals that can be missed even with periapical radiographs obtained from different angles (14). Furthermore, preparing a well-shaped endodontic access cavity and investigating its floor carefully are also effective in the detection of additional canal orifices. Balleri *et al.* (15) reported that T shaped endodontic cavity is ideal in terms of cleaning and gaining easy access to the pulp chamber and canals of the premolar teeth with three roots and canals. As suggested by Balleri *et al.* (15) a cut at the bucco-proximal angle, from the entrance of buccal canals to cavo-surface angle, was made in the present cases. So the outline of endodontic cavity was formed. This T-shaped access technique is useful to reach all the root canals properly (15). In straight-on radiographs of maxillary premolars, it was reported by Sieraski *et al.* (16) that whenever the mesio-distal width of the mid-root image was equal to the mesio-distal width of the crown or greater than it, the tooth probably has three roots.

Conclusion

Presence of a second buccal canal and root is a rare anatomical variation that can be seen in maxillary first premolars. Endodontists should always consider the possibility of unusual number of roots and canals to overcome infections and related symptoms. It is

of utmost importance to diagnose and treat the teeth having such variations in order to maintain the balance of oral environment.

Source of funding

None declared.

Conflict of interest

None declared.

References

1. Cantatore G BE, Castellucci A. Missed anatomy: Frequency and clinical impact. *Endod Topics* 2006;15(1):3-31.
2. Marca C, Dummer PM, Bryant S, Vier-Pelisser FV, So MV, Fontanella V, Dutra VD, de Figueiredo JA. Three-rooted premolar analyzed by high-resolution and cone beam ct. *Clin Oral Investig* 2013;17(6):1535-1540.
3. Pecora JD, Saquy PC, Sousa Neto MD, Woelfel JB. Root form and canal anatomy of maxillary first premolars. *Braz Dent J* 1992;2(2):87-94.
4. Vier-Pelisser FV, Dummer PM, Bryant S, Marca C, So MV, Figueiredo JA. The anatomy of the root canal system of three-rooted maxillary premolars analysed using high-resolution computed tomography. *Int Endod J* 2010;43(12):1122-1131.
5. Kartal N, Ozcelik B, Cimilli H. Root canal morphology of maxillary premolars. *J Endod* 1998;24(6):417-419.
6. Javidi M, Zarei M, Vatanpour M. Endodontic treatment of a radicular maxillary premolar: A case report. *J Oral Sci* 2008;50(1):99-102.
7. Oruçoğlu H ÇF. Maxillary first premolar with three roots: A case report. *Hacettepe Diş Hek. Fak. Derg* 2005;29(4):26-29.
8. Vertucci FJ. Root canal morphology and its relationship to endodontic procedures. *Endod Topics* 2005;10(1):3-29.
9. Ahmad IA, Alenezi MA. Root and root canal morphology of maxillary first premolars: A literature review and clinical considerations. *J Endod* 2016;42(6):861-872.
10. Özcan E ÇH, Hamidi MM. Root and canal morphology of maxillary first premolars in a turkish population. *J Dent Sci* 2012;7(4):390-394.
11. Sert S, Bayirli GS. Evaluation of the root canal configurations of the mandibular and maxillary permanent teeth by gender in the turkish

- population. J Endod 2004;30(6):391-398.
12. Bulut DG, Kose E, Ozcan G, Sekerci AE, Canger EM, Sisman Y. Evaluation of root morphology and root canal configuration of premolars in the turkish individuals using cone beam computed tomography. Eur J Dent 2015;9(4):551-557.
 13. Ok E, Altunsoy M, Nur BG, Aglarci OS, Colak M, Gungor E. A cone-beam computed tomography study of root canal morphology of maxillary and mandibular premolars in a turkish population. Acta Odontol Scand 2014;72(8):701-706.
 14. Kakkar P, Singh A. Maxillary first molar with three mesiobuccal canals confirmed with spiral computer tomography. J Clin Exp Dent 2012;4(4):e256-259.
 15. Balleri P GA, Ferrari M. Primer premolar superior com tres raices. Endod Pract 1997;3:13-15.
 16. Sieraski SM, Taylor GN, Kohn RA. Identification and endodontic management of three-canalled maxillary premolars. J Endod 1989;15(1):29-32.

Corresponding Author:**Zeliha UĞUR**

Department of Endodontics
Faculty of Dentistry
Abant İzzet Baysal University
14000, Bolu/Turkey
Phone: +90 374 254 10 00
e-mail: zlhugur@gmail.com