

# Effects of early unilateral mandibular first molar extraction on condylar and ramal vertical asymmetry

Koray Halicioglu<sup>1</sup>, Mevlut Celikoglu<sup>2</sup>, Suleyman K. Buyuk<sup>3</sup>, Ahmet E. Sekerci<sup>4</sup>, Celal Candirli<sup>5</sup>

<sup>1</sup>Department of Orthodontics, Faculty of Dentistry, Abant Izzet Baysal University, Bolu, Turkiye,

<sup>2</sup>Department of Orthodontics, Faculty of Dentistry, Karadeniz Technical University, Trabzon, Turkiye,

<sup>3</sup>Department of Orthodontics, Faculty of Dentistry, Erciyes University, Kayseri, Turkiye,

<sup>4</sup>Department of Oral and Maxillofacial Radiology, Faculty of Dentistry, Erciyes University, Kayseri, Turkiye,

<sup>5</sup>Department of Oral and Maxillofacial Surgery, Faculty of Dentistry, Karadeniz Technical University, Trabzon, Turkiye

**Correspondence:** Dr. Koray Halicioglu

Email: korayhalicioglu@hotmail.com

## ABSTRACT

**Objective:** The objective of the following study is to investigate the mandibular vertical asymmetry in a group of patients with early unilateral mandibular first molar extractions. **Materials and Methods:** Mandibular asymmetry index measurements (condylar, ramal and condylar-plus-ramal) were performed on the panoramic radiographs of a study group including 51 patients (mean age:  $18.60 \pm 1.11$  years) and a control group of 51 patients (mean age:  $18.53 \pm 1.29$  years). Group I included patients with a unilateral mandibular first molar extracted before the age of 12 years. Group II included patients with no extractions and had excellent Class I relationships, no missing teeth and slight or moderate anterior crowding. A paired *t*-test was used to determine possible statistically significant differences between the sides for the measurements. Student's *t*-test was used for the comparison of asymmetry index values between the groups and genders. **Results:** No group showed statistically significant sex-or side-specific differences for posterior vertical height measurements. Condylar asymmetry index and ramal asymmetry index measurements were not statistically different between the groups, while condylar-plus-ramal asymmetry index (CRAI) measurements were statistically different between the groups ( $P = 0.019$ ). **Conclusions:** A slight difference for CRAI value was found in patients with early unilateral mandibular first molar extractions.

**Key words:** Condylar asymmetry, first molar extraction, ramal asymmetry, vertical asymmetry

## INTRODUCTION

Improvement in the beauty and harmony of facial appearance has been intended since the beginning of orthodontics practice.<sup>[1]</sup> Stedman Medical Dictionary<sup>[2]</sup> defines symmetry as equality or correspondence in the form of parts distributed around a venter or an axis, at the two extremes or poles, or on the two opposite sides of the body. Facial complex consists of numerous constituent parts and

harmony among these parts determines the overall symmetry.

Clinically, symmetry means balance, while significant asymmetry means imbalance.<sup>[3]</sup> Teeth play a vital role in this symmetry. Andrews<sup>[4]</sup> stressed the importance of the first molars in a balanced and normal occlusion. More than 50% of children over the age of 11 years have the experience of caries in the first molars.<sup>[5]</sup> Unfortunately, the first molars are the most common

**How to cite this article:** Halicioglu K, Celikoglu M, Buyuk SK, Sekerci AE, Candirli C. Effects of early unilateral mandibular first molar extraction on condylar and ramal vertical asymmetry. Eur J Dent 2014;8:178-83.

Copyright © 2014 Dental Investigations Society.

DOI: 10.4103/1305-7456.130595

early extracted teeth due to dental caries.<sup>[6]</sup> Early extraction of these teeth could negatively affect the balance of all occlusion.<sup>[7]</sup>

Lundstrom<sup>[8]</sup> classified the possible causes of asymmetries of the face and dental arch as genetic, environmental, or a combination. The environmental factors include tooth caries, early tooth loss and trauma.<sup>[9]</sup> Early extraction of permanent first molars might also cause problems, such as tipping of adjacent teeth toward the extraction site, extrusion of the corresponding opposite teeth, asymmetric chewing habits and periodontal problems from alveolar bone atrophy in the extraction cavity.<sup>[7,10,11]</sup> The asymmetrical function and imbalanced occlusion may cause asymmetric development in the right and left sides of the mandible. In addition, asymmetries between both sides of the mandible may be due to an adaptive response of the mandible, which may cause modeling of the condyle.<sup>[12]</sup>

Asymmetry of the craniofacial skeleton is most readily diagnosed from the frontal rather than from the other view. A method to determine asymmetries between the mandibular condyles and the rami was introduced by Habets *et al.*<sup>[13]</sup> This method compares the vertical heights of the mandibular right and left condyles and rami and uses those observations to determine condylar asymmetry in unilateral<sup>[14,15]</sup> and bilateral<sup>[15,16]</sup> cross bite, Class II<sup>[17]</sup> and Class III<sup>[18]</sup> malocclusions, different skeletal patterns,<sup>[19]</sup> cleft lip and palate<sup>[20]</sup> and temporomandibular-disorder patients.<sup>[13]</sup>

Furthermore, some of the authors investigated the morphologic asymmetries of the mandible in patients with no missing teeth using various methods.<sup>[21-25]</sup> Çağlaroğlu *et al.*<sup>[26]</sup> investigated the effects of early loss of maxillary and mandibular first molars on skeletal asymmetry using postero-anterior radiographs. In a recent paper by Halicioglu *et al.*<sup>[27]</sup> investigate the mandibular vertical asymmetry in a group of adult patients who had early bilateral mandibular first molar extractions. They reported that asymmetry index measurements were not statistically different between the groups and the lengths of the condylar, ramal and condylar plus ramal height were less in the study group than in a well-matched control group of without extraction.

Although studies about condylar asymmetry have increased in the past years, until date no study has been carried out to compare the effects of unilateral early loss of a mandibular first molar on condylar asymmetry. Therefore, this study was aimed at

investigating the effects of early loss of a mandibular first molar on condylar and ramal heights and determining whether patients with early loss of a mandibular first molar had asymmetrical condyles, by using the method described by Habets *et al.*<sup>[13]</sup>

## MATERIALS AND METHODS

The sample consisted of a study group including 51 patients of which 23 were females and 28 males; (mean age:  $18.60 \pm 1.11$  year) and a control group comprised of 51 patients of which 24 were females and 27 males; (mean age:  $18.53 \pm 1.29$  years). Group I included patients with a unilateral mandibular first molar extracted before the age of 12 years. Group II was the control group with no extractions and had excellent Class I relationships, no missing teeth and slight or moderate anterior crowding. These two groups were randomly selected from the archives of the patient data, in the archives of the Abant Izzet Baysal, Karadeniz Technical, and Erciyes Universities. The patients in the control group were not orthodontically treated. Approval from the ethics committee was not needed for the present retrospective study.

The additional criteria, also suggested and practiced by Çağlaroğlu *et al.*,<sup>[26]</sup> for both the study and control groups, were the following: (1) Post-pubertal period; (2) skeletal Class I relationship determined by ANB angle; (3) no developmental or acquired craniofacial or neuromuscular deformities; (4) no previous orthodontic treatment; (5) no signs or symptoms of temporomandibular dysfunction; (6) no lateral mandibular shift during closure as determined by clinical examination; and (7) no carious lesions, extensive restorations, or pathologic periodontal status.

As panoramic radiographs (PRs) are routinely used as a diagnosis procedure in our clinics, all the patients had PR available for evaluation. All radiographs were taken by experienced radiology technicians on panoramic systems. The patients were positioned with the lips in a rest position and the head oriented to the Frankfort horizontal plane, as suggested by Azevedo *et al.*<sup>[28]</sup>

All films were traced and measured by the same author. On both the left and right sides, the most lateral points of the condyle and ramus were marked as X and Y, respectively. On each side, a line (ramus tangent) was drawn passing through points X and Y and termed as the A-line. Another line was drawn from the most superior points of the condylar images

perpendicular to the A-line and termed as the B-line. The intersection of the A- and B-line was named point Z. The distances between points X and Z were measured and recorded as condylar height (CH). Similarly, the distances between points X and Y and that between points Z and Y were measured and recorded as ramus height (RH) and CH + RH, respectively [Figure 1]. The asymmetry indices of the condyle, ramus and condylar-plus-ramus were computed using the following formula developed by Habets *et al.*<sup>[13]</sup> To measure the condylar, ramal and condylar-plus-ramal asymmetry, the following formula was used:

$$\text{Asymmetry index} = \left| \frac{\text{Right} - \text{Left}}{\text{Right} + \text{Left}} \right| \times 100$$

### Statistical analysis

The normality test of Shapiro-Wilks and Levene's variance homogeneity test were performed and all data were found normally distributed. Thus, parametric tests were used for statistical analyses. The paired *t*-test was used to determine possible statistically significant differences between the sides for condylar, ramal and condylar-plus-ramal height measurements. Student's *t*-test was used for the comparison of asymmetry index values between the groups and the genders.

At 3 weeks after the first measurements, 15 randomly selected PRs were retraced and re-measured by the same author in order to calculate the method error by using Dahlberg's formula.<sup>[29]</sup> The Dahlberg's method error values were within acceptable limits and the difference between the 1<sup>st</sup> and 2<sup>nd</sup> measurements of the 15 radiograms was insignificant. In addition, the difference between the two readings was tested for significance with paired *t*-test and no difference was found ( $P > 0.05$ ). All statistical analyses were

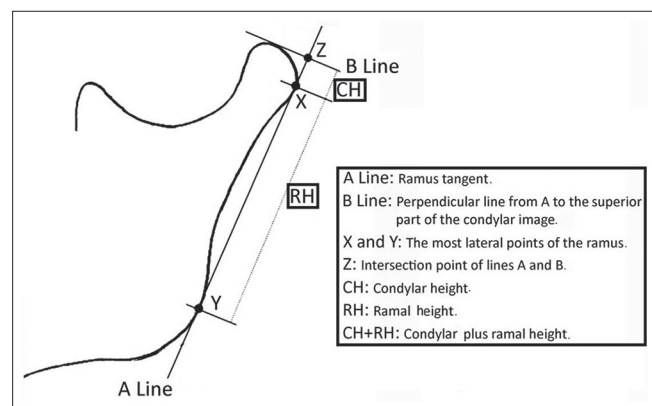


Figure 1: Measuring method

performed by means of the statistical package for the social sciences (SPSS) software package for Windows (version 13.0, SPSS, Chicago, Illionis). *P* value was considered to be significant if  $<0.05$ .

## RESULTS

The means and standard deviations of the chronological ages in each group were shown in Table 1. Comparison of the mean ages between the groups showed that there were no statistically significant differences in the distribution of the chronological ages between the study and control groups ( $P > 0.05$ ).

The descriptive mandibular asymmetry indices for both male and female patients were calculated separately in both groups to investigate the relationship between the genders. The results of the Student's *t*-tests showed no statistically significant differences between the mean values of the male and female patients ( $P > 0.05$ ) [Table 2]. Therefore, the data for both sexes were pooled for further statistical analyses.

Means, standard deviations and statistical results of paired *t*-test comparing the measurements of the left and right sides in the extraction and non-extraction groups are tabulated in Table 3. There was no

Table 1: Means and standard deviations of the mean ages in the study and control groups

Group	Gender	N	Mean age (year)	P1	P2
Control	Female	24	18.37±1.24	0.424	0.758
	Male	27	18.67±1.33		
	Total	51	18.53±1.29		
Study	Female	23	18.50±1.11	0.446	
	Male	28	18.75±1.12		
	Total	51	18.60±1.11		

P1: Results of the student's *t* test comparing the mean age between genders, P2: Results of the Student's *t* test comparing the mean age between study and control groups

Table 2: Descriptive statistics and comparisons of asymmetry indices in the study and control groups according to gender

Group	Female			Male			P
	Variable	Mean	SD	Variable	Mean	SD	
Control	CAI	7.69	6.90	CAI	7.57	8.11	0.486
	RAI	3.35	1.88	RAI	2.70	2.19	
	CRAI	2.07	1.58	CRAI	2.68	1.48	
Study	CAI	8.35	5.53	CAI	9.08	7.97	0.176
	RAI	2.84	2.93	RAI	2.58	2.49	
	CRAI	3.31	1.75	CRAI	3.11	2.09	

CAI: Condylar asymmetry index, RAI: Ramal asymmetry index, CRAI: Condylar-plus-ramal asymmetry index, SD: Standard deviation

**Table 3: Statistical side comparisons of the study and control groups**

Variable	Study group (Mean and SD)		P	Control group (Mean and SD)		P
	Extraction side	Non-extraction side		Right side	Left side	
CH	4.82±0.96	4.81±0.90	0.149	4.93±0.89	4.63±0.85	0.14045
RH	43.95±5.61	44.97±4.82	0.464	45.36±3.85	43.67±4.57	0.37891
CH+RH	48.77±5.30	49.78±5.81	0.513	50.29±4.25	48.30±4.25	0.28298

CH: Condylar height, RH: Ramal height, CH+RH: Condylar-plus-ramal height, SD: Standard deviation, P: Results of paired t test

statistically significant difference observed between the right and left sides in condylar, ramal and condylar-plus-ramal height measurements between the groups ( $P > 0.05$ ).

In the extraction group, the condylar-plus-ramal asymmetry index (CRAI) value was found to be  $3.22 \pm 1.28$ , whereas this value was  $2.39 \pm 1.54$  for the control group without extraction ( $P = 0.019$ ). On the other hand, no statistically significant difference was found for the condylar asymmetry index (CAI) and ramal asymmetry index (RAI) measurements between the study and control groups ( $P > 0.05$ ) [Table 4].

## DISCUSSION

A study done by Kambylafkas *et al.*<sup>[30]</sup> reported that PRs can be used to determine the condylar asymmetry. We observed that PRs were often used by investigators who performed mandibular<sup>[25,31]</sup> and condylar<sup>[14-20,32]</sup> asymmetry studies. However, computed tomography (CT) is the gold standard for determination of condylar asymmetries,<sup>[33]</sup> although radiation exposure could be an issue. CTs may be obtained only in specific cases, whereas PRs may be utilized for a routine dental examination. Therefore, PRs were used to determine the condylar asymmetry, together with other dental reasons because of associated costs, ethical considerations and exposure of patients to relatively low doses of radiation.

In addition, the PR images of the structures in both vertical and horizontal directions could be magnified.<sup>[34]</sup> In the vertical plane, magnification is dependent on the projection factors alone. The distance between the focal point of the X-ray tube and the film is always the same.<sup>[35]</sup> Larheim and Svanaes<sup>[36]</sup> suggested that the reproducibility of vertical measurements is acceptable, provided that the patient's head is positioned properly in the equipment. In the present study, special attention was given to the positioning of the patients during exposure. Habets *et al.*<sup>[13,37]</sup> found that vertical differences between the left and right sides were <6% if positions were altered <10 mm from their original centered position. In the present study, the differences

**Table 4: Descriptive statistics and comparisons of asymmetry index values between the study and control groups**

Asymmetry index	Group	n	Mean (%)	SD	P
CAI	Study	51	8.65	6.58	0.474
	Control	51	7.63	7.49	
RAI	Study	51	2.73	2.73	0.574
	Control	51	3.01	2.06	
CRAI	Study	51	3.22	1.88	0.019
	Control	51	2.39	1.54	

CAI: Condylar asymmetry index, RAI: Ramal asymmetry index, CRAI: Condylar-plus-ramal asymmetry index, SD: Standard deviation, P: Results of Student's t test

between the sides were <6% in both groups and this finding confirms that special attention was given in the present study.

The present study is the first to investigate vertical condylar and ramal asymmetry using the method of Habets *et al.*,<sup>[13]</sup> in patients with unilateral early loss of mandibular first molar. Sample size was investigated by power analysis and samples and sex subgroups were sufficient to detect differences. The previous studies<sup>[13-15,32]</sup> found that no statistically significant differences were present between the genders with the same method. In agreement with those studies, we found that the asymmetry indices were not affected by gender. On the contrary, Sağlam<sup>[19]</sup> searched for condylar asymmetry in various skeletal patterns and declared that CRAI measurements were significantly affected by sex.

In a recent paper, Wang *et al.*<sup>[38]</sup> indicated that there is an association between asymmetry of occlusion and condyles. Some authors<sup>[39,40]</sup> showed that a malocclusion such as a Class II subdivision or a posterior crossbite might cause real mandibular asymmetry in growing patients due to the above-mentioned adaptive condylar changes. O'Byrn *et al.*<sup>[41]</sup> evaluated mandibular asymmetry in adults with unilateral crossbite. They found that the mandible was rotated and thus, the condyle on the crossbite side was positioned more posteriorly, when compared with the contralateral side. However, these authors found no mandibular skeletal asymmetry. Similarly, Letzer and Kronman<sup>[42]</sup>

also found no relationship between asymmetry and malocclusion. In the present study, patients were without skeletal malocclusion, such as Class II, Class III and unilateral or bilateral crossbite to eliminate the effects of those malocclusions on the condylar, ramal and condylar-plus-ramal height and asymmetry indices.

According to Habets *et al.*,<sup>[37]</sup> a 3% index ratio can result from a 1 cm change in head position while the PR is being taken and thus, asymmetry index values (CAI, RAI and CRAI) >3% should be considered as mandibular posterior vertical asymmetry. Our findings show that in patients with unilateral early loss of mandibular first molar (CAI:  $8.65 \pm 6.58\%$ ) and in those with no extracted or missing teeth (CAI:  $7.63 \pm 7.49\%$ ), the patients have very asymmetrical mandibular condyles according to CAI values. The CAI values were higher when compared with the 3% threshold value of Habets *et al.*<sup>[37]</sup> in both groups. However, the comparison between study and control groups was not statistically significant. In other words, patients with early unilateral loss of mandibular first molar were found to have asymmetric mandibles according to the CAI measurements and those with no missing teeth were also observed to have asymmetry. Concordant with the present findings, Sağlam,<sup>[19]</sup> Uysal *et al.*,<sup>[15]</sup> Kurt *et al.*<sup>[20]</sup> and Halicioglu *et al.*<sup>[27]</sup> found CAI of  $7.96 \pm 6.73\%$ ,  $7.57 \pm 8.39\%$ ,  $9.95 \pm 10.42\%$  and  $7.04 \pm 6.79\%$  in the control groups with Class I, respectively. These high values indicating asymmetry in both the groups can be attributed to shape, angular and positional differences between the right and left condyles without any related malocclusion.<sup>[43]</sup>

Cağlaroğlu *et al.*<sup>[26]</sup> showed that patients with early loss of a first molar had both dental and skeletal asymmetries, using postero-anterior cephalograms. They found that skeletal asymmetries mainly occurred in the lower anterior region. In the present study, condylar, ramal and condylar-plus-ramal heights in all the groups were similar on the right and left sides or extraction and non-extraction sides and no statistically significant side differences were found. Nevertheless, the RAI and CRAI measurements used for evaluating posterior vertical dimension of the mandible were similar and close to this 3% threshold value in both study and control groups.

In our study, the CRAI of patients with early unilateral mandibular first molar extraction was found to be  $3.22 \pm 1.88\%$ . This value was statistically higher than the CRAI value for the control group ( $2.39 \pm 1.54\%$ ) ( $P = 0.019$ ). This situation may be explained as follows: A first molar extraction space is closed mainly by mesialization of

the posterior teeth and a small part of this space is closed by distal movement of the premolars.<sup>[26]</sup> More tipping occurs in the mandible than in the maxilla in the neighboring teeth and premature contacts become more distinct. The premature contacts may cause horizontal mandibular displacements during the last closing phase when the mandible occludes in maximum intercuspal position.<sup>[11]</sup> Furthermore, Inui *et al.*<sup>[44]</sup> reported that continuous displacement of the condyles in the glenoid fossa during growth and development, caused by occlusal problems, could induce asymmetric growth of the mandible and condyles.

The weakness of the present study is that it was performed on two dimensional films. Our results might be compared with the studies that will be performed on CT by three dimensional analyses. Future studies should be done using cone beam computed tomography (CBCT). The new generation of these CBCT machines has a radiation dose lower than PRs.

## CONCLUSIONS

Based on the above study it can be concluded that condylar index values were significantly higher when compared with the 3% threshold value of Habets *et al.*<sup>[37]</sup> in both the study and the control groups, but comparisons between the groups were not statistically significant. However, the CRAI value was found to be slightly asymmetric in patients with early unilateral loss of mandibular first molar (about 1%) that would not be clinically important.

## REFERENCES

1. Bishara SE, Cummins DM, Jakobsen JR, Zaher AR. Dentofacial and soft tissue changes in Class II, division 1 cases treated with and without extractions. *Am J Orthod Dentofacial Orthop* 1995;107:28-37.
2. Stedman G. *Stedman's Medical Dictionary*. Baltimore: The Williams and Wilkins Company; 1966.
3. Erickson GE, Waite DE. Mandibular asymmetry. *J Am Dent Assoc* 1974;89:1369-73.
4. Andrews LF. The six keys to normal occlusion. *Am J Orthod* 1972;62:296-309.
5. Todd JE, Dodd T. *Children's Dental Health in the United Kingdom*. London: Office of Population Censuses and Surveys; 1983.
6. Albadri S, Zaitoun H, McDonnell ST, Davidson LE. Extraction of first permanent molar teeth: Results from three dental hospitals. *Br Dent J* 2007;203:E14.
7. Lin YT, Lin WH, Lin YT. Immediate and six-month space changes after premature loss of a primary maxillary first molar. *J Am Dent Assoc* 2007;138:362-8.
8. Lundstrom A. Some asymmetries of the dental arches, jaws, and skull, and their etiological significance. *Am J Orthod Dentofacial Orthop* 1961;47:81-106.
9. Halicioglu K, Toptas O, Akkas I, Celikoglu M. Permanent first molar extraction in adolescents and young adults and its effect on the development of third molar. *Clin Oral Investig* 2013; [Epub ahead of print].

10. Janson G, Carvalho PE, Cançado RH, de Freitas MR, Henriques JF. Cephalometric evaluation of symmetric and asymmetric extraction treatment for patients with Class II subdivision malocclusions. *Am J Orthod Dentofacial Orthop* 2007;132:28-35.
11. Rebellato J. Asymmetric extractions used in the treatment of patients with asymmetries. *Semin Orthod* 1998;4:180-8.
12. Pirttiniemi P, Kantomaa T. Relation of glenoid fossa morphology to mandibulofacial asymmetry, studied in dry human Lapp skulls. *Acta Odontol Scand* 1992;50:235-43.
13. Habets LL, Bezuur JN, Naeiji M, Hansson TL. The orthopantomogram, an aid in diagnosis of temporomandibular joint problems. II. The vertical symmetry. *J Oral Rehabil* 1988;15:465-71.
14. Kiki A, Kiliç N, Oktay H. Condylar asymmetry in bilateral posterior crossbite patients. *Angle Orthod* 2007;77:77-81.
15. Uysal T, Sisman Y, Kurt G, Ramoglu SI. Condylar and ramal vertical asymmetry in unilateral and bilateral posterior crossbite patients and a normal occlusion sample. *Am J Orthod Dentofacial Orthop* 2009;136:37-43.
16. Kilic N, Kiki A, Oktay H. Condylar asymmetry in unilateral posterior crossbite patients. *Am J Orthod Dentofacial Orthop* 2008;133:382-7.
17. Miller VJ, Smidt A. Condylar asymmetry and age in patients with an Angle's Class II division 2 malocclusion. *J Oral Rehabil* 1996;23:712-5.
18. Miller VJ, Bodner L. Condylar asymmetry measurements in patients with an Angle's Class III malocclusion. *J Oral Rehabil* 1997;24:247-9.
19. Sağlam AM. The condylar asymmetry measurements in different skeletal patterns. *J Oral Rehabil* 2003;30:738-42.
20. Kurt G, Bayram M, Uysal T, Ozer M. Mandibular asymmetry in cleft lip and palate patients. *Eur J Orthod* 2010;32:19-23.
21. Vig PS, Hewitt AB. Asymmetry of the human facial skeleton. *Angle Orthod* 1975;45:125-9.
22. Farkas LG, Cheung G. Facial asymmetry in healthy North American Caucasians. An anthropometrical study. *Angle Orthod* 1981;51:70-7.
23. Vazquez F, Grostic JD, Fonder AC, DeBoer KF. Eccentricity of the skull. Correlation with dental malocclusion. *Angle Orthod* 1982;52:144-58.
24. Kusayama M, Motohashi N, Kuroda T. Relationship between transverse dental anomalies and skeletal asymmetry. *Am J Orthod Dentofacial Orthop* 2003;123:329-37.
25. Ramirez-Yañez GO, Stewart A, Franken E, Campos K. Prevalence of mandibular asymmetries in growing patients. *Eur J Orthod* 2011;33:236-42.
26. Çağlaroğlu M, Kilic N, Erdem A. Effects of early unilateral first molar extraction on skeletal asymmetry. *Am J Orthod Dentofacial Orthop* 2008;134:270-5.
27. Halicioglu K, Celikoglu M, Caglaroglu M, Buyuk SK, Akkas I, Sekerci AE. Effects of early bilateral mandibular first molar extraction on condylar and ramal vertical asymmetry. *Clin Oral Investig* 2013;17:1557-61.
28. Azevedo AR, Janson G, Henriques JF, Freitas MR. Evaluation of asymmetries between subjects with Class II subdivision and apparent facial asymmetry and those with normal occlusion. *Am J Orthod Dentofacial Orthop* 2006;129:376-83.
29. Dahlberg G. *Statistical Methods for Medical and Biological Students*. New York: Interscience Publications; 1940.
30. Kambylafkas P, Murdock E, Gilda E, Tallents RH, Kyrkanides S. Validity of panoramic radiographs for measuring mandibular asymmetry. *Angle Orthod* 2006;76:388-93.
31. Van Elslande DC, Russett SJ, Major PW, Flores-Mir C. Mandibular asymmetry diagnosis with panoramic imaging. *Am J Orthod Dentofacial Orthop* 2008;134:183-92.
32. Sezgin OS, Celenk P, Arici S. Mandibular asymmetry in different occlusion patterns. *Angle Orthod* 2007;77:803-7.
33. Sanders DA, Rigali PH, Neace WP, Uribe F, Nanda R. Skeletal and dental asymmetries in Class II subdivision malocclusions using cone-beam computed tomography. *Am J Orthod Dentofacial Orthop* 2010;138:542.e1-20.
34. Langland OE, Sippy FH. Anatomic structures as visualized on the orthopantomogram. *Oral Surg Oral Med Oral Pathol* 1968;26:475-84.
35. Lund TM, Manson-Hing LR. A study of the focal troughs of three panoramic dental x-ray machines. Part I. The area of sharpness. *Oral Surg Oral Med Oral Pathol* 1975;39:318-28.
36. Larheim TA, Svanaes DB. Reproducibility of rotational panoramic radiography: Mandibular linear dimensions and angles. *Am J Orthod Dentofacial Orthop* 1986;90:45-51.
37. Habets LL, Bezuur JN, van Ooij CP, Hansson TL. The orthopantomogram, an aid in diagnosis of temporomandibular joint problems. I. The factor of vertical magnification. *J Oral Rehabil* 1987;14:475-80.
38. Wang MQ, He JJ, Chen CS, Widmalm SE. A preliminary anatomical study on the association of condylar and occlusal asymmetry. *Cranio* 2011;29:111-6.
39. Alavi DG, BeGole EA, Schneider BJ. Facial and dental arch asymmetries in Class II subdivision malocclusion. *Am J Orthod Dentofacial Orthop* 1988;93:38-46.
40. Pirttiniemi P, Kantomaa T, Lahtela P. Relationship between craniofacial and condyle path asymmetry in unilateral cross-bite patients. *Eur J Orthod* 1990;12:408-13.
41. O'Byrn BL, Sadowsky C, Schneider B, BeGole EA. An evaluation of mandibular asymmetry in adults with unilateral posterior crossbite. *Am J Orthod Dentofacial Orthop* 1995;107:394-400.
42. Letzer GM, Kronman JH. A posteroanterior cephalometric evaluation of craniofacial asymmetry. *Angle Orthod* 1967;37:205-11.
43. Yale SH. Radiographic evaluation of the temporomandibular joint. *J Am Dent Assoc* 1969;79:102-7.
44. Inui M, Fushima K, Sato S. Facial asymmetry in temporomandibular joint disorders. *J Oral Rehabil* 1999;26:402-6.

## Access this article online

## Quick Response Code:



Website:  
www.eurjdent.com

Source of Support: Nil.  
Conflict of Interest: None declared